

## The Effect of Pomegranate Peel Extract on Collagen Total, Interleukin-6 and Vascular Endothelial Growth Factor Receptor (VEGF) Levels



Risyarningsi Sangkota<sup>1</sup>, Chodidjah<sup>2</sup>, Atina Husaana<sup>3</sup>

<sup>1,2,3</sup>Faculty of Medicine, Universitas Islam Sultan Agung, Jl Kaligawe KM 4, Semarang, 50012

**ABSTRACT:** Treatment and rehabilitation of burns requires perseverance, high costs, trained and skilled personnel, therefore a breakthrough is needed to address this problem in an effective, safe and affordable way. One of the breakthrough alternatives is to use natural ingredients such as pomegranate peels. The purpose of this study was to determine the effect of giving pomegranate peel extract orally on levels of IL-6, VEGF and the amount of collagen of male Sprague Dawley rats that were given second degree burns. The design of this study was experimental with a post-test only control group design approach. The subjects of the study were 24 male Sprague Dawley rats which were randomly divided into 4 groups. Group K, P1, P2, and P3. Groups P1, P2, and P3 were given second degree burns and given pomegranate peel extract at doses of 54, 108, 162 mg/200 g BW. On the 3rd day an IL-6 examination was carried out at PSPG UGM and on the 7th day a termination was carried out and an examination was carried out for VEGF and the amount of collagen at the SSCR FK UNISSULA in January 2022. The One Way Anova test showed levels of IL-6, VEGF and the amount of collagen in between groups, there is a significant difference with each value of  $p=0.000$ ,  $p=0.029$  and  $p=0.000$  ( $p<0.05$ ). Administration of pomegranate peel extract at doses of 54, 108, 162 mg/200 g BW can reduce IL-6 levels, increase VEGF, and increase the amount of collagen of male Sprague Dawley rats that were given second degree burns.

**KEYWORDS:** Pomegranate skin extract, interleukin-6, VEGF, collagen total

### I. INTRODUCTION

Burns are tissue damage caused by exposure to or contact with heat sources such as fire, hot water, hot oil, electricity, chemicals and radiation (Scapin et al., 2018). Burns cause skin tissue damage which triggers an inflammatory reaction by releasing proinflammatory mediators, especially *Interleukin-6* (IL-6). The proliferative phase of wound healing is characterized by angiogenesis starting from the response of the *Vascular Endothelial Growth Factor* (VEGF) to the formation of collagen (Revilla, 2018). The use of antibiotics as a medicine for burns can cause drug resistance, so an alternative is needed to use medicinal plants such as Pomegranate peel. Pomegranate peel contains polyphenols, anti-inflammatory properties, and high antibacterial activity, but the effect on IL-6, VEGF, and collagen levels is unknown (Buhaudin, 2021).

Treatment and rehabilitation of burns requires persistence, high costs, and trained and skilled personnel. World Health Organization (WHO) reports that burns are ranked 9th in terms of deaths in the world, for people aged 5–14 years with an estimated 41,575 deaths, 15th for people aged 15–29 years with an estimated 49,067 deaths, and 15th for people aged 0–4 years with an estimated 62,655 deaths. The death rate from burns is estimated to be 5% of all the 7th most common injuries in the world (Wardhana et al., 2017). The use of antibiotics as a medicine for burns can cause drug resistance, so other alternatives are needed for the use of medicinal plants such as Pomegranate peel (Afriansyah et al., 2021).

Pomegranate is widely known by the people of Indonesia as a traditional medicine because it is believed to contain certain substances. Several studies have revealed the high polyphenol content, antioxidant activity, anti-inflammatory content, and high anti-bacterial activity in pomegranate (Putri, 2013). Research conducted by Krisna states that the active substances punicalagin, ellagic acid, gallic acid, urolithin A/B, granatin A/B and delphinidin from flowers, seeds, peels, mesocarp (inner skin) and whole pomegranate are proven to be able to reduce levels of IL-6 in diseases with inflammatory pathophysiology (Krisna et al., 2021). Research conducted by Puspitasari also showed that there was an effect of the ethanol extract of red pomegranate seeds at a concentration of 40% on wound healing time in Wistar strain rats (Puspitasari, 2019).

## The Effect of Pomegranate Peel Extract on Collagen Total, Interleukin-6 and Vascular Endothelial Growth Factor Receptor (VEGF) Levels

Skin tissue damage caused by burns produces large numbers of apoptotic and necrotic cells. Necrotic tissue and surrounding tissue that are also damaged become a trigger for the body to release various Damage Associated Molecular Patterns (DAMPs), such as exposed DNA, Reactive Oxygen Species (ROS), ATP, and N-formyl peptides which induce the production of pro-inflammatory cytokines. such as IL-6 in maintaining the inflammatory response (Krisna et al., 2021).

Pomegranate peel contains polyphenols which play a role in helping the process of wound healing (angiogenesis) by repairing epidermal and dermal cells and tissues through *vascular endothelial growth factor* (VEGF). However, specifically there has been no research that reveals how effective pomegranate is in treating burns, especially in terms of affecting IL-6, VEGF, and collagen levels, so the results of this study are expected to become a new alternative that supports the treatment of burns orally. where pomegranate has a function as a standardized, tested, affordable traditional medicinal ingredient, and has minimum side effects. This study will look at the effect of giving pomegranate peel extract orally on levels of *interleukin-6* (IL-6), VEGF and collagen in male *Sprague Dawley* rats who received second degree burns.

### II. MATERIALS AND METHODS

This type of research is experimental with a posttest only control group design. The sample of this study were 24 male *Sprague Dawley* rats which were acclimatized at the PSPG laboratory as experimental animals at Gadjah Mada University, Yogyakarta and allocated to 4 groups, 1 negative control group and 3 treatment groups randomly sampling allocation. Data on the average levels of IL-6, VEGF and the amount of collagen are presented descriptively in tabular (graphic) form. Then the data was tested for normality with *Shapiro Wilk* and the data homogeneity was tested with the *Levene test*. The distribution of data on levels of IL-6, VEGF and the amount of collagen was normal and homogeneous, so it was continued with the parametric test *One Way Anova* which was obtained with a p value <0.05 followed by *Tukey test*.

#### Research Instruments

Rat cages with feed containers sizes L: 40 cm, W: 30 cm, H: 30 cm, rat scales "Nigushi Scale", gloves, pipettes, Eppendorf, spectrophotometers, micropipette, ELISA reader, shaver, alcohol swab 70%, ketamine 10%, syringe, circle plate stainless steel 2 cm, Erlenmeyer, heater, notch heater (COD reactor HACH®), and thermometer.

#### Sample Preparation

The research sample must be included in the inclusion criteria and taken by simple random as many as 24 of male *Sprague Dawley* rats categorized into four group with the number of samples for each group are six, consisting of one control group and three treatment groups, then adapted first for seven days. Experimental animals were given standard feed consisting of 20-25% protein, 45-55% starch, 10-12% fat, and 4% crude fiber and plain water for every day.

#### Pomegranate Peel Extract

Pomegranate Peel Extract in powder form is obtained from the standardized Herbilogy Pomegranate Peel Extract Powder brand. Pomegranate peel extract powder mixed with distilled water and stirred with the help of a magnetic stirrer until dissolved. Preparation of pomegranate peel extract doses of 54 mg/200 g BW, 108 mg/200 g BW, and 162 mg/200 g BW obtained from the conversion of doses from humans to rats given orally for 6 days.

#### 2<sup>nd</sup> Degree Burns

Rats were anesthetized first on the area to be burned with a dose of 0.2 cc of lidocaine in 2 cc of distilled water. Prepare a round stainless steel with 2 cm of diameter that heated up to 85°C. The plate is then attached to the previously shaved skin for five seconds (Lukiswanto et al., 2019).

#### Interleukin-6 (IL-6) levels

The measurement of IL-6 levels using ELISA kit Rat IL-6 with units of ng/L. The sample was obtained by blood centrifugation of male *Sprague Dawley* rats taken from the orbital vein on day three.

#### Vascular Endothelial Growth Factor Receptor (VEGF)

The observation of VEGF was used the back skin of male *Sprague Dawley rats* tissue preparation which were given the second degree burns for seven day by using immunohistochemistry staining.

#### Collagen Total

The observation and measurement of collagen total was used the back skin of male rats *Sprague Dawley* tissue preparation which were given the second degree burns for seven day by using Sirius Red staining.

# The Effect of Pomegranate Peel Extract on Collagen Total, Interleukin-6 and Vascular Endothelial Growth Factor Receptor (VEGF) Levels

## Result Observation and Calculation

VEGF and the amount of collagen was calculated using the fast-digital analysis method, each preparation was photographed using an LC evolution camera and an Olympus Bx51 photomicroscope with an objective magnification of 400 times, each preparation was photographed 3 times and saved in JPEG format. ImageJ 1.52a software (*National Institute of Health, USA*).

## III. RESULT

The study of the effect of giving pomegranate peel extract orally on levels of interleukin-6 (IL-6), VEGF and the amount of collagen in male Sprague Dawley rats that were given second degree burns was carried out for 7 days. The results of the study are listed in Table 1.

**Table 1. The results analysis of mean of IL-6, VEGF, and collagen total**

Variable	Group				Sig.(p)
	K	P1	P2	P3	
	N=6 Mean	N=6 Mean	N=6 Mean	N=6 Mean	
<b>IL-6 Levels</b>	79.03	54.99	42.48	40.49	
Std.deviasi	0.96	0.81	0.51	0.59	
Shapiro Wilk	0.772*	0.869*	0.804*	0.988*	
Levene Test					0.352*
One Way Anova					0.000*
					**
<b>VEGF Levels</b>	13.69	17.47	19.00	18.27	
Std.deviasi	2.13	3.25	3.48	2.34	
Shapiro Wilk	0.741*	0.799*	0.675*	0.935*	
Levene Test					0.486*
One Way Anova					0.020*
					**
<b>Collagen Total</b>	38.80	50.32	55.21	58.41	
Std.deviasi	3.20	7.21	4.88	2.67	
Shapiro Wilk	0.270*	0.115*	0.767*	0.622*	
Levene Test					0.109*
One Way Anova					*
					0.000*
					**
<b>Description:</b> *Normal p>0,05 **Homogeneous p>0,05 ***Significant p<0,05					

Table 1 showed that the lowest average of IL-6 level were the third treatment group (P3) by administering pomegranate peel extract at a dose of 162 mg/200 g BW, followed by the second treatment group (P2) with a dose of 108 mg/200 g BW and then the first treatment group (P1) with a dose of 54 mg/200 g BW. The control group (K) with distilled water obtained the highest average IL-6 level. One-Way Anova test result showed the significant differences between each group (p=0.000).

The highest average of VEGF levels (Table 1) were the second treatment group (P2) with a dose of 108 mg/200 g BW of pomegranate peel extract, followed by the third treatment group (P3) with a dose of 162 mg/200 g BW, and the first treatment group (P1) with a dose of 54 mg/200 g BW. The control group (K) with distilled water resulted in the lowest average of VEGF levels. One-Way Anova test showed the significant differences of VEGF levels between each group (p=0.020).

The highest average of collagen total (Table 1) were the third treatment group (P3) with a dose of 162 mg/200 g BW of pomegranate peel extract, followed by the second treatment group (P2) with a dose of 108 mg/200 g of pomegranate peel extract. and the first treatment group (P1) with a dose of 54 mg/200 g BW. The control group (K) with distilled water obtained the lowest

## The Effect of Pomegranate Peel Extract on Collagen Total, Interleukin-6 and Vascular Endothelial Growth Factor Receptor (VEGF) Levels

average of total collagen. One-Way Anova test showed the significant differences in the total of collagen between each group ( $p=0.000$ ).

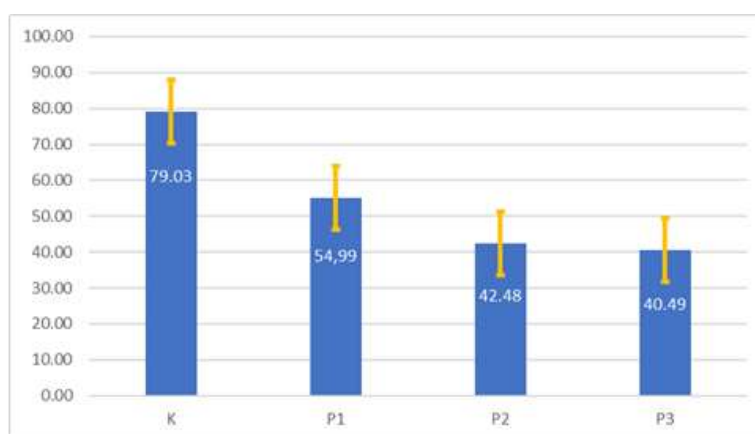
### IL-6 Levels

The difference levels of IL-6 levels between two group was determined by *post hoc* test using the Tukey test as presented in Table 2. Tukey test result showed that there is a significant difference of IL-6 levels between control group (K) with first, second, and third treatment group (P1, P2, P3). The results in the first treatment group (P1) were significant difference with second and third treatment group (P2, P3). The second treatment group (P2) had a significant difference with the third treatment group (P3). Based on the data in Table 2, it can be concluded that administration of pomegranate peel extract at a dose of 54 mg/200 g BW, 108 mg/200 g BW, 162 mg/200 g BW had a significant effect on decreasing IL-6 levels in male rats *Sprague Dawley* that received the second degree burns.

**Table 2. The differences of IL-6 levels between two group**

Group	<i>p-value</i>
K vs P1	0.000*
K vs P2	0.000*
K vs P3	0.000*
P1 vs P2	0.000*
P1 vs P3	0.000*
P2 vs P3	0.001*

\*Tukey test with significant value  $p < 0.05$



**Figure 1. The average levels of IL-6 between groups**

Based on Figure 1 showed that the average of IL-6 levels in the control group (K) is 79.03 mg/200 g BW, the first treatment group (P1) is 54.99 mg/200 g BW, the second treatment group (P2) is 42.48 mg/200 g 200 g BW, and the third treatment group (P3) is 40.49 mg/200 g BW.

### VEGF Levels

The difference of VEGF levels between two group was determined by using the Tukey test as shown in Table 3.

**Table 3. the differences in VEGF levels between two groups**

Group	<i>p-value</i>
K vs P1	0.134
K vs P2	0.021*
K vs P3	0.052
P1 vs P2	0.789
P1 vs P3	0.961
P2 vs P3	0.970

\*Tukey test with significant value  $p < 0.05$

## The Effect of Pomegranate Peel Extract on Collagen Total, Interleukin-6 and Vascular Endothelial Growth Factor Receptor (VEGF) Levels

*Tukey test* result in Table 3 showed that there were no significant differences of VEGF levels between control group (K) with first and third treatment group (P1, P3) but there is a significant difference with the second treatment group (P2). The results in the first treatment group (P1) showed no significant difference with the second treatment group (P2) and the third treatment group (P3). There was no significant difference between the second treatment group (P2) with the third treatment group (P3). It can be concluded that the administration of pomegranate peel extract at a dose of 54 mg/200 g BW, 108 mg/200 g BW, 162 mg/200 g BW had a significant effect on increasing the VEGF levels in male *Sprague Dawley* rats which were given the second degree burn.

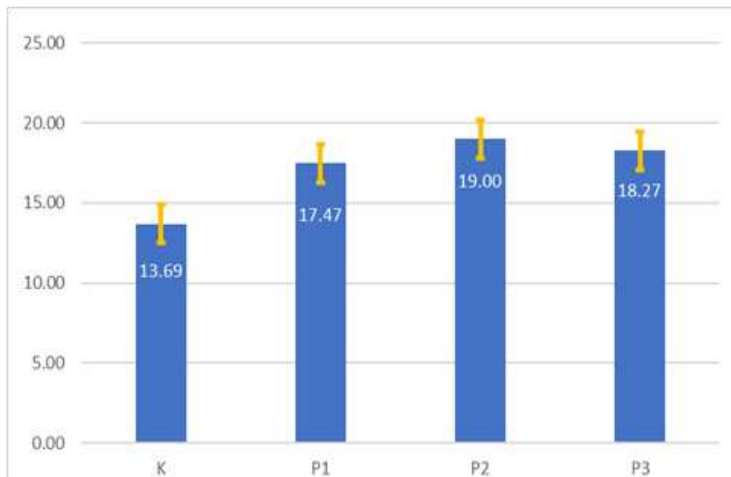


Figure 2. the average of VEGF levels between groups

Based on Figure 2 showed that the average of VEGF levels. The average of VEGF in the control group (K) is 13.69 mg/200 g BW, the first treatment group (P1) is 17.47 mg/200 g BW, the second treatment group (P2) is 19.00 mg/200 g BW, and the third treatment group (P3) is 18.27 mg/200 g BW.

### Collagen Total

The difference in the total of collagen between two group was determined by using *Tukey test* as presented in Table 4.

Table 4. The difference of collagen total between groups

Group	<i>p</i> -value
K vs P1	0.003*
K vs P2	0.000*
K vs P3	0.000 *
P1 vs P2	0.322
P1 vs P3	0.040*
P2 vs P3	0.665

\**Tukey test* with significant value  $p < 0.05$

*Tukey test* result (Table 4) showed the difference of collagen total between groups. There is a significant difference between the control group (K) with the first, second, and third treatment group (P1, P2, P3). The results in the first treatment group (P1) showed there is no significant difference with the second treatment group (P2) but showed a significant difference with the third treatment group (P3). The second treatment group (P2) showed no significant difference with the third treatment group (P3). It can be concluded that administration of pomegranate peel extract at doses of 54 mg/200 g BW, 108 mg/200 g BW, and 162 mg/200 g BW significantly affected to increase the amount of collagen in male *Sprague Dawley* rats which were given the second degree burns.

## The Effect of Pomegranate Peel Extract on Collagen Total, Interleukin-6 and Vascular Endothelial Growth Factor Receptor (VEGF) Levels

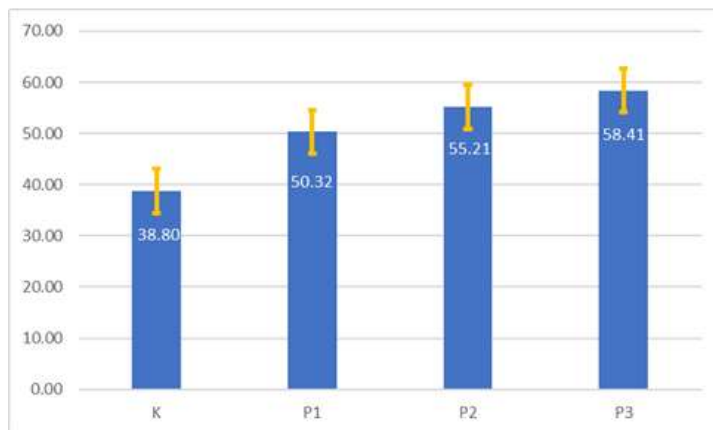


Figure 3. The average total of collagen between groups

Based on Figure 2, the average levels of VEGF in the control group (K) is 38.80 mg/200 g BW, the first treatment group (P1) 50.32 mg/200 g BW, the second treatment group (P2) 55.21 mg/200 g BW and the third treatment group (P3) 58.41 mg/200 g BW. Histopathological picture of VEGF skin tissue of the male *Sprague Dawley* rats stained with IHC is presented in Figure 4.

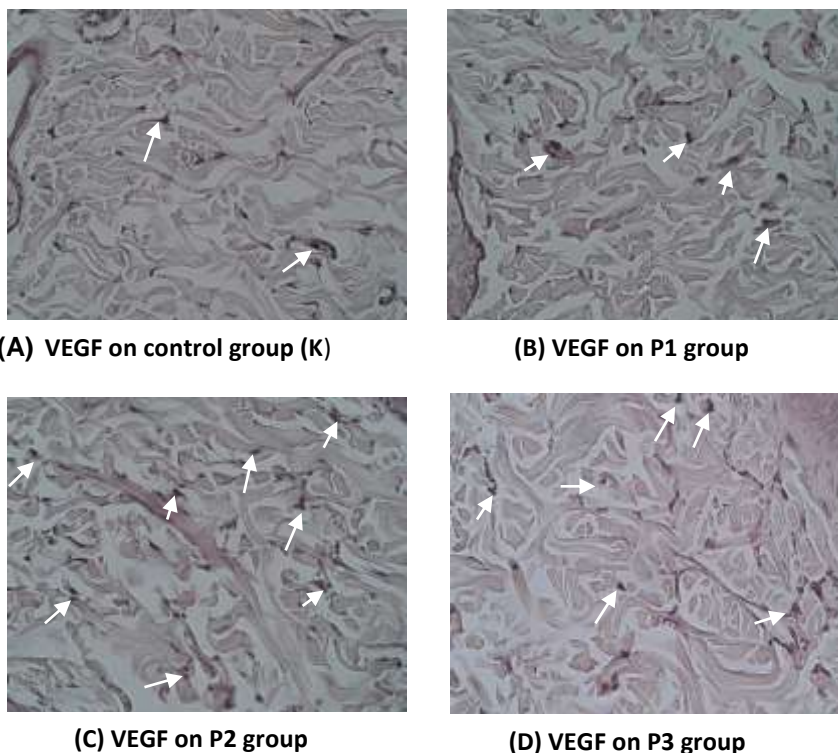


Figure 4. Differences in VEGF control group and treatment group in male *Sprague Dawley* rats with IHC staining, using a 400x magnification light microscope. The sign (arrow) is positive for brown VEGF.

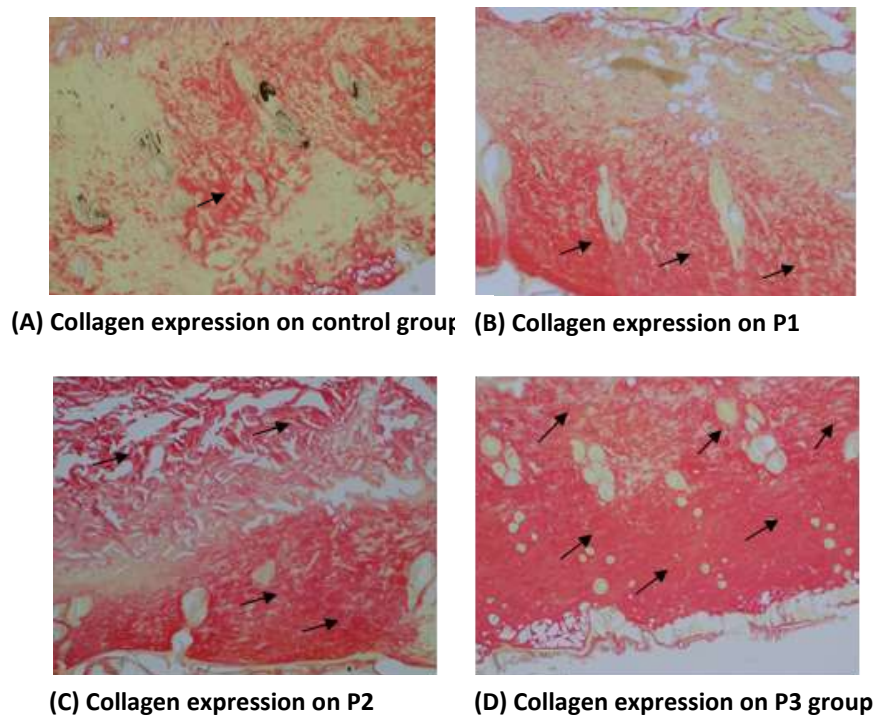
The expression of VEGF by immunohistochemical staining is indicated by the brown color that accumulates in the cytoplasm that diffuses out of the cell (Figure 4). VEGF expression was calculated by the amount of cytoplasm in cells that were positively stained at three fields of view at 400x magnification on an Olympus Bx51 photo microscope and area expression analysis was averaged with ImageJ 1.52a software (*National Institute of Health, USA*). In the control group (K) there were fewer, while in the first group (P1) they were given pomegranate peel extract at a dose of 54 mg/200 g BW, the second treatment group (P2) was given pomegranate peel extract at a dose of 108 mg/200 g BW and the third treatment group (P3) by giving pomegranate peel extract at a dose of 162 mg/200 g BW immediately after being exposed to second degree burns, appeared to be more.

The observation result of collagen total using Sirius red staining of dermis skin tissue of male *Sprague Dawley* rats presented in Figure 5. The amount of dermal collagen is the percentage of collagen tissue pixels in the form of bright red tissue with Sirius



## The Effect of Pomegranate Peel Extract on Collagen Total, Interleukin-6 and Vascular Endothelial Growth Factor Receptor (VEGF) Levels

red staining compared to the pixels of the entire tissue seen in histological preparation photos. The assessment was carried out on photographs and calculations by digital analysis using ImageJ 1.52a software (*National Institute of Health, USA*), then calculated on three fields of view at 400x magnification, the average was taken. It can be seen in the Figure 4 that the control group (K) is smaller than the first treatment group (P1), given pomegranate peel extract at a dose of 54 mg/200 g BW, the second treatment group (P2) is given pomegranate peel extract at a dose of 108 mg/200 g BW and the third treatment group (P3) were given pomegranate peel extract at a dose of 162 mg/200 g BW.



**Figure 5. The differences in collagen expression of the control group and the treatment group of male Sprague Dawley rats staining Sirius Red, using a 400x magnification light microscope. The arrows show positive collagen expression in bright red.**

### IV. DISCUSSION

Burns are damage to the integrity of the skin or other organic tissues caused by acute trauma (Anggowarsito, 2014). Second degree burns are burns that involve destruction of the epidermis and the upper layers of the dermis and injury to the deeper dermis. The wound feels painful, looks erythema or reddish and has fluid exudation (Hendra et al., 2014). The results of examining IL-6 levels in the control group (K) who were given second degree burns by administering distilled water experienced a significant increase compared to the group given pomegranate peel extract at a dose of 54 mg/200 g BW (P1), 108 mg/200 g BW (P2), and 162 mg/200 g BW (P3) (Table 1). Interleukin 6 (IL-6) is a cytokine that plays a role in the early inflammatory phase. The main source of IL-6 comes from various types of cells such as macrophages, fibroblasts, keratinocytes and endothelial cells. Excessive production of the cytokine IL-6 indicates inflammation. IL-6 cytokines have a function in regulating the immune system such as in the differentiation of neutrophils and monocytes and affect the work of other cytokines and chemokines that work in the inflammatory phase to proliferation (Rahman, 2019).

The decrease in IL-6 levels in the P3 group which was given second degree burns and given pomegranate peel extract at a dose of 162 mg/200 g BW experienced a significant difference from the treatment group at a dose of 54 mg/200 g BW (P1) and the treatment group at a dose 108 mg/200 g BW (P2) (Table 1). This is because the inflammatory process is working optimally so that the inflammatory response does not last longer. In a prolonged inflammatory response, macrophages will continue to release IL-6 which influences inflammation by attracting inflammatory cells so that inflammatory cells will continue to accumulate in eliminating pathogens. So low levels of IL-6 can indicate that the wound has entered the final inflammatory phase and is soon moving into the initial proliferative phase (Rahman, 2019). This happens because the benefits of pomegranate peel extract include antioxidants, anti-inflammatories, and can function to boost the immune system. Research conducted by Almahita (2013) proved that an aqueous extract of pomegranate peel orally can inhibit the increase in the number of macrophages from the inflammatory phase to the proliferative phase so that the inflammatory process does not continue in the healing process of burns (Putri, 2013).

## The Effect of Pomegranate Peel Extract on Collagen Total, Interleukin-6 and Vascular Endothelial Growth Factor Receptor (VEGF) Levels

In addition, in the same study it was proven that the anti-inflammatory activity possessed by *Ellagic Acid* was not as strong as pomegranate extract in inhibiting increased expression of interleukin-6 (IL-6) and transforming *growth factor-beta 1* (TGF- $\alpha$ 1) due to biliary obstruction (Yuniarti et al., 2013).

The results of the VEGF examination in the control group (K) who were given second degree burns by administering distilled water experienced a significant decrease compared to the group given pomegranate peel extract at a dose of 54 mg/200 g BW (P1), 108 mg/200 g BW (P2), and 162 mg/200 g BW (P3) (Table 1). Vascular Endothelial Growth Factor (VEGF) plays a role in increasing endothelial cell migration, proliferation, and blood vessel permeability. VEGF binds specifically and soluble to fibrinogen with high affinity, retaining its capacity to support endothelial cell proliferation when both bound and soluble with surface immobilized fibrinogen. This interaction facilitates the localization and mitogenic activity of VEGF in injured tissue (Aisyah, 2014).

The treatment groups P1, P2, and P3 were given pomegranate peel extract which was given second degree burns and experienced an increase in VEGF (Table 1). This proves that pomegranate peel extract is good for increasing VEGF expression in wound healing, because apart from flavonoids and polyphenols, pomegranate peel extract also has *Ellagic Acid* which can stimulate proliferation in the wound healing process. (Putri, 2013) According to Pusparatri (2018) Gel Pomegranate skin (*Punica granatum L.*) contains flavonoids and tannins in which there is *ellagic acid* which can stimulate fibroblast proliferation in the wound healing process (Pusparatri, 2018). VEGF expression in the P2 group seemed to be higher than in the P3 group but in the *Post Hoc* the difference was not significant.

The results of examining the amount of collagen in the control group (K) who were given second degree burns by administering distilled water experienced a significant decrease compared to the group given pomegranate peel extract at a dose of 54 mg/ 200 g BW (P1), 108 mg/ 200 g BW ( P2), and 162 mg/200 g BW (P3) (Table 1). This indicates damage to the dermis layer of the skin where there are scabs or eschar, the epidermis of the skin is hypertrophied caused by the proliferation of epithelial cells, and in the dermis layer it can be seen that collagen has formed but not as thick as seen in the negative control. According to Han et al (2005), scabs or eschar that form on the skin area of a burn wound are formed of fibrin and platelets from a hemostatic response and infiltration of mononuclear cells and necrotic tissue (Fatmawati, 2018).

The increase in the amount of collagen in the P2 group that was given second degree burns and given pomegranate peel extract at a dose of 108 mg/200 g BW experienced no significant difference with the treatment group at a dose of 54 mg/200 g BW (P1) and was significant different from the treatment group with a dose 162 mg/ 200 g BW (P3) (Table 1). This study shows that pomegranate peel extract orally plays a role in increasing collagen synthesis. Collagen that is in the skin is useful in the wound healing process so that when the skin is injured it can heal by itself. This is also supported by the research of Shinde, et al (2020) which states that pomegranate peel contains antioxidant activity due to its phenolic content. Examples such as flavonoids are associated with antioxidant abilities, polyphenols are found in pomegranate peels e.g. ellagic, ellagic acid and gallic acid. The use of polyphenols and flavonoids is useful for antioxidants in wound healing and antimicrobials (Supia&Yuniartika, 2020). A similar study by Almahita (2013) reported that aqueous extract of pomegranate peel plays a role in the proliferation of fibroblasts and the process of collagen synthesis by stimulating the synthesis of pro-collagen type I and inhibits MMP-1, a collagen degrading enzyme (Putri, 2013).

The limitation of this study is that the wound healing process is generally divided into several phases, which is interrelated, namely the inflammatory, proliferation, and maturation phases. Wound healing time takes up to 25 days, but this study was only conducted for 7 days, as a result, only partial tissue healing effects were observed. The research using time series design is needed to determine the duration of the effect of pomegranate peel extract in healing burns.

## IV. CONCLUSION

Oral administration of pomegranate peel extract at doses of 54 mg/200 g BW, 108 mg/200 g BW, and 162 mg/200 g BW can reduce levels of *Interleukin-6* (IL-6) and can increase VEGF and the amount of collagen in male *Sprague Dawley* rats who received second degree burns.

## ACKNOWLEDGEMENT

The author would like to thank everyone who has provided criticism and suggestions during the process of preparing the manuscript.

## REFERENCES

- 1) Scapin S, Echevarría-Guanilo ME, Boeira Fuculo Junior PR, Gonçalves N, Rocha PK, Coimbra R. Virtual Reality in the



## The Effect of Pomegranate Peel Extract on Collagen Total, Interleukin-6 and Vascular Endothelial Growth Factor Receptor (VEGF) Levels

- treatment of burn patients: A systematic review. *Burns*. 2018;44(6):1403-1416. doi:10.1016/j.burns.2017.11.002
- 2) Revilla G. Effect of Bone Marrow Mesenchymal Stem Cells on VEGF Secretion in Rat Burn Healing. *J Health Andalas*. 2018;6(3):702. doi:10.25077/jka.v6.i3.p702-706.2017
  - 3) Wardhana A, Basuki A, Prameswara ADH, Rizkita DN, Andarie AA, Canintika AF. The epidemiology of burns in Indonesia's national referral burn center from 2013 to 2015. *Burn Open*. 2017;1(2):67-73. doi:10.1016/j.burnso.2017.08.002
  - 4) Putri AC. Effect of Pomegranate Peel Aqueous Extract (*Punica Granatum*) Orally on Macrophages, Fibroblasts and Collagen in Healing Burns in White Rats. 2013.
  - 5) Krisna AI, Widyaningrum I, Wahyuningsih D, et al. Systematic Literature Review: Effect of Pomegranate (*Punica Granatum* L.) Polyphenols on Interleukin-6 Levels in Diseases Involving Pathophysiology. *J Community Doctor*. 2021;6:1-12.
  - 6) Puspitasari B. Effect of 40% Red Pomegranate (*Punica granatum* L.) Seed Ethanol Extract on Wound Healing Time of Wistar Strain Rats (*Rattus norvegicus*). 2019.
  - 7) Ronggowarsito JL. Burns A Dermatological Viewpoint. *J Widya Med*. 2014;2(2):115-120.
  - 8) Lukiswanto BS, Miranti A, Sudjarwo SA, Primarizky H, Yuniarti WM. Evaluation of wound healing potential of pomegranate (*Punica granatum*) whole fruit extract on skin burn wounds in rats (*Rattus norvegicus*). *J Adv Vet Anim Res*. 2019;6(2):202-207. doi:10.5455/javar.2019.f333
  - 9) Hendra A, Sumarno, Dewi D. Effects of Ginger Extract (*Zingiber officinale* Rosc.) on Reducing Signs of Inflammatory Erythema in Wistar Strain White Mice (*Rattus norvegicus*) with Second Degree Burns. *FKUB Health Maj*. 2014;1(4):214-222.
  - 10) Rahman AFN. Differences in the therapeutic effect of VCO (Virgin Coconut Oil) Ointment and Placenta Extract Topical Preparations on Degree II-B Burns in Mice (*Rattus Norvegicus*) in terms of the Expression of Interleukin-6 (Il-6) and the Number of Neutrophil Cells. 2019.
  - 11) Yuniarti WM, Handajani R, Kusumo Broto HO, Suidiana K. Standardized Pomegranate Extract Reduces Degrees of Liver Fibrosis in Animal Models of White Mice. *J Vet*. 2013;14(4):511-518.
  - 12) Aisyah S. Effect of green grass jelly leaf extract (*Cyclea barbata* Miers) on increasing expression of vascular endothelial growth factor (VEGF) in second-degree burns in Wistar rats. 2014.
  - 13) Pusparatri AP. The Effect of Pomegranate Peel Gel (*Punica Granatum* L.) on the Number of Fibroblasts in the Healing Process of Heat-Induced Wistar Rat (*Rattus Norvegicus*) Traumatic Ulcers. 2018.
  - 14) Fatmawati D. *The Effect of Ointment Therapy of Cassava Leaf Extract (Manihot Esculenta) on Decreased Malondialdehyde (MDA) Levels and Histopathology of Skin Collagen in Male White Rats (Rattus Norvegicus) With Second Degree Burns.*; 2018.
  - 15) Supia DR, Yuni Artika W. Literature Study: Treatment of Grade II Burns with Pomegranate. *12th Univ Res Colloquium 2020*. 2020:58-67.
  - 16) Ardi Afriansyah, M., Kamaruddin, M., Norma Ethica, S., & Fitria Aprianti, N. (2021). BACTERIAL ANTI-BIOFILM ACTIVITY FROM BROWN ALGAE *Dictyota* sp. *Medika Alkhairaat: Journal of Medical and Health Research*, 3(3), 89–93. <https://doi.org/10.31970/ma.v3i3.82>
  - 17) Bahaudin I. The Effect of Pomegranate Extract (*Punica granatum* L.) on the Seminiferous Tubules of Male Mice (*Mus musculus* L.) Exposed to Cigarette Smoke. *Raden Intan State Islamic University, Lampung*. 2021.



There is an Open Access article, distributed under the term of the Creative Commons Attribution – Non Commercial 4.0 International (CC BY-NC 4.0) (<https://creativecommons.org/licenses/by-nc/4.0/>), which permits remixing, adapting and building upon the work for non-commercial use, provided the original work is properly cited.