

The Value of Clinical Anatomy, Imaging, Breast Gland Surgery and Therapeutic Implications in Breast Cancer



Gabriel Stătescu^{1,3}, Dragoş Valentin Crauciuc¹, Dragoş Munteanu², Marius Constantin Moraru¹, Andrei Scripcaru¹, Alin Horaţiu Nedelcu¹, Dragoş Andrei Chiran¹, Mariana Postolache⁴, Cristinel Ioan Stan¹, Anca Sava^{1,5}

¹"Grigore T. Popa" University of Medicine and Pharmacy Iaşi, Department of Anatomy, 16 Universitatii Street, Iaşi, Romania

²Clinic of Internal Medicine at General Railway University Hospital Iasi, Romania

³First Clinic of Surgery, "St. Spiridon" University Emergency Clinical Hospital Iaşi, Romania

⁴Ministry of Health, Programme Implementation Unit, 1-3 Cristian Popisteanu Street, Code 010024, Bucharest, Romania

⁵Laboratory of Pathology, Prof. Dr. Nicolae Oblu Emergency Clinical Hospital, Iaşi, Romania

ABSTRACT: Breast cancer is a common disease in women over the age of 50. The risk of breast cancer in women between the ages of 30 to 39 is 1 in 250 women, and in women between the ages of 40 to 49 is 1 in 70 women.

Material and method: We analysed clinicopathological data of the breast cancer on a series of 32 cases that underwent surgery between 2020–2021 in General Surgery Department of "Providenta" Hospital Iasi, Romania. This includes the mammary gland and the cellular-adipose tissue placed between the glandular lobes and lobules together with blood and lymphatic vessels, and nerves. The study was conducted after the surgery on the parts resected through it, but we also used the explorations performed for diagnosis and stage evaluation such as breast ultrasound, mammography, staging CT. The patients ranged between 58 and 71 years old and came from rural areas. The anatomopathological examination confirmed the preoperative diagnosis, the patients being referred to oncology for evaluation followed by adjuvant treatment.

Results: The postoperative evolution was favourable, and no immediate postoperative complications were reported. Aspiration drainage was removed on average after 3 days. The average length of hospital stay was 7 days.

Discussions: The surgery was performed using the Madden technique and was a radical mastectomy with axillary lymph node removal. This technique offers a very good loco-regional clearance from the oncological point of view because it resects in block the mammary gland, the adipose tissue next to it, the skin on a wide surface as well as the neighbouring fascial system, also preserving the pectoral muscle. The axillary lymph-adenectomy is complete, with no risk of intraoperative dissemination.

Conclusion: Radical mastectomy with axillary lymph node removal using the Madden technique, performed in the beginning stage is a modern, effective surgery, easily supported by patients who were informed from the beginning, with an average duration of two hours and reduced postoperative complications.

KEYWORDS: breast adenocarcinoma, Madden mastectomy, estrogen receptor, progesterone receptor, anti Ki67 antibodies.

INTRODUCTION

Breast cancer (BC) is a common disease in women over the age of 50. The risk of breast cancer increases with age [1]. The risk of BC in women between the ages of 30 to 39 is 1 in 250 women [2], and in women between the ages of 40 to 49 the risk is 1 in 70 women. This disease is rarer in women under 35 years of age. All women over 40 and over are at risk for this condition, but most cases are in women over 50. The risk of BC is increased in women 60 years and over [3], [4], [5]. Breast cancer is the most frequently diagnosed cancer in women and ranks second among causes for cancer related death in women [6], [7]. Although, there are cases of BC in men, 99% of cases occur in women. The natural history of BC begins with the first malignant cell to appear under the action of risk factors and ends with the destruction of the host organism. Breast cancer is the abnormal proliferation of malignant cells in the epithelium of the ducts and lobules of a breast [8].

The Value of Clinical Anatomy, Imaging, Breast Gland Surgery and Therapeutic Implications in Breast Cancer

AIM

Our research was aimed at surgical technic of breast tumours based on radical mastectomy by Madden operation and immunohistochemical analyses.

PATIENTS, MATERIALS AND METHODS

We analyzed clinicopathological data of the breast cancer on a series of 32 cases that underwent surgery between 2010 – 2012 in General Surgery Department of Providenta Hospital Iasi, Romania . This includes dates about the mammary gland and the cellular-adipose tissue placed between the glandular lobes and lobules together with blood and lymphatic vessels, and nerves from medical electronic datas and imagistics used. We analyzed clinicopathological data of the breast cancer on a series of 32 cases that underwent surgery between 2010 – 2012 in General Surgery Department of Providenta Hospital Iasi, Romania . This includes dates about the mammary gland and the cellular- adipose tissue placed between the glandular lobes and lobules together with blood and lymphatic vessels, and nerves from medical electronic datas and imagistics used. We analysed clinical and pathological features of women diagnosed with breast cancer on a series of 32 cases that underwent surgery between 2010–2021 in General Surgery Department of "Providenta" Hospital Iasi, Romania. The patients ranged from 58 to 71 years old, and came from rural areas.

We analysed the anatomy of the breast on our series of 32 breast cancer cases operated on in the last ten years. This includes dates about breast tissue together with tumoral invasion in blood and lymphatic vessels, and nerves from medical electronic data and imagistics used.

The patients were informed that the likelihood of cancer was high, so they accepted radical surgery from the very beginning. The operation performed was Madden radical mastectomy with axillary lymph node removal. This technique based on radical mastectomy offers a very good loco-regional clearance from the oncological point of view because it resects in block the mammary gland, the adipose tissue next to it, the skin on a wide surface as well as the neighbouring fascial system, also preserving the pectoral muscle. The axillary lymphadenectomy is complete, with no risk of intraoperative dissemination.

The study was performed on postoperative resection pieces, but we also used the explorations performed for diagnosis and stage evaluation such as breast ultrasound, mammography, staging CT.

Subsequently, the anatomopathological examination confirmed the preoperative diagnosis, so the patients were referred to oncology for evaluation and continued with adjuvant treatment.

The appearance of orange peel that can occur in breast cancer is explained by the enlargement of hair follicles caused by dermal edema as a consequence of lymphatic stasis secondary to lymphatic blockage caused by tumor or malignant cells. The skin of the breast in the submammary groove loses its mobility and is fixed to the fascia of the pectoralis major muscle by connective fibers. For this reason, when we performed the mastectomy for breast cancer, we cut and lifted it together with the mammary gland and the fascia of the pectoralis major muscle. Most of the lymph of the mammary parenchyma flows centripetally to the areolar and subareolar superficial plexus, and from here it goes centrifugally to the periphery of the mammary gland through the circumareolar lymphatics which anastomoses with the fascial plexus belonging to the pectoralis muscle.

There is a fine lymphatic network located on the pectoral fascia that does not participate in the early spread of breast cancer due to the very small size of these vessels. At the periphery of the gland, the lymph vessels are grouped schematically in a number of afferent pathways leading to the regional lymph nodes. The main axillary pathway is the most important drainage channel from the mammary lymph to the axilla. It consists of two large lymph trunks that form at the periphery of the subareolar plexus, one lateral that collects lymph from the upper half of the breast and another that collects lymph from the lower and inner edge of the subareolar plexus that runs to the axillary ganglia surrounding the mammary areola. The main internal mammary tract consists of the vessels that drain the lymph from the central and medial quadrants of the breast. They accompany the perforating blood vessels crossing the pectoralis major muscle in the inner part of the mammary region by shedding lymph into the chain of the internal mammary ganglia. They are 4 in number, with a diameter between 2 and 5 mm and are usually located in each of the first 3 intercostal spaces, the 4th ganglion being at the level of the 5th or 6th intercostal space. These are also called parasternal ganglia. From the axillary ganglion groups start lymphatic collecting trunks that pass through the axillary tip between the subclavicular and clavicular muscle and flow at the confluence between the internal jugular vein and the subclavicular vein.

Representative sections of breast tissue were used for IHC stainings, to identify the origin of the BM in a previous BC [anti-cytokeratin 5/6 (CK5/6) and anti-mammaglobin antibodies], the immunoexpression of estrogen receptor (anti-ER antibody) and progesterone receptor (anti-PR antibody), but also the tumor proliferation (anti-Ki67 antibody) (Table 1, 2).

IHC reactions were performed using the EnVision™+ Dual Link System–Horseradish Peroxidase (HRP) (Dako, Denmark) for mammaglobin, cytokeratin 5/6 (CK5/6) and ER, and UltraVision Quanto Detection System–HRP (Thermo Scientific, UK) for PR and

The Value of Clinical Anatomy, Imaging, Breast Gland Surgery and Therapeutic Implications in Breast Cancer

Ki67 labeling index (LI), according to manufacturers' recommendations. Antigen retrieval was realized with sodium citrate buffer, pH 6, using a water bath at 95°C. In the end, 3,3'-Diaminobenzidine (DAB) was used as chromogen and Mayer's Hematoxylin for nuclear counterstaining against nuclear staining. Normal breast tissue was used as positive controls. IHC reactions were considered positive only when a brown staining of the cytoplasm (in case of anti-CK5/6 and anti-mammaglobin antibodies) or of the nucleus (in case of anti-ER, anti-PR, and anti-Ki67 antibodies) were obtained.

Table 1. The antibodies used for immunohistochemical staining of the analysed breast adenocarcinoma

Antibody	Manufacturer	Clone	Antigen retrieval	Class	Dilution	Labeling	Cellular localization
<i>Anti-CK AE1/AE3</i>	Dako	AE1/AE3	Citrate, pH6	Monoclonal mouse anti-human CK AE1/AE3	1:50	Epithelial cells	Cytoplasmic
<i>Anti-CK7</i>	Novocastra	RN7	Citrate, pH6	Monoclonal mouse antibody	1:100	Epithelial cells	Cytoplasmic and membranous
<i>Anti-CK20</i>	Novocastra	KS208	Citrate, pH6	Monoclonal mouse anti-human CK20	1:100	Epithelial cells	Cytoplasmic
<i>Anti-CDX2</i>	Cell Marque	EPR2764Y	Citrate, pH6	Monoclonal rabbit antibody	1:500	Intestinal epithelium	Nuclear
<i>Anti-HER2/neu</i>	Thermo Fisher Scientific	SP3	Citrate, pH6	Monoclonal rabbit antibody	1:700	Epithelial cells	Cell membrane
<i>Anti-S100</i>	Novocastra	-	-	Polyclonal rabbit antibody S100 protein	1:200	Neural crest cell	Nuclear and cytoplasmic
<i>Anti-HMB45</i>	Genemed	HMB45	-	Mouse anti-melanosome	1:50	Melanic cells	Cytoplasmic
<i>Anti-melan A</i>	Dako	A103	pH 9	Mouse monoclonal anti-human melan A	1:50	Melanic cells	Cytoplasmic
<i>Anti-Ki67</i>	Thermo Fisher Scientific	SP6	Citrate, pH6	Monoclonal rabbit antibody Ki67	1:250	Proliferating cells	Nuclear

CK: Cytokeratin; CDX2: Caudal-type homeobox 2; HER2: Human epidermal growth factor receptor 2; HMB45: Human melanoma black 45.

Table 2. Immunohistochemical profile of breast adenocarcinoma

Histological type of breast adenocarcinoma	CK7	CK20	CDX2	HER2/neu (aberrant nuclear accumulation)	Ki67 (%)	Li	Melan A	HMB45	S100 protein
ADC									
•Conventional type, moderately differentiated	-	+++	+++	+++/++/-	90-100%	-	-	-	-

The Value of Clinical Anatomy, Imaging, Breast Gland Surgery and Therapeutic Implications in Breast Cancer

• <i>Serrated</i>	-	+++	+++	+++	95%	-	-	-
• <i>Mucinous</i>	-	+++	+++	+++	90%	-	-	-
• <i>Cribriiform comedo-type</i>	-	+++	+++	+++	95%	-	-	-
Melanoma	-	-	-	-	Not done	+++	+++	+++

ADC: Adenocarcinoma; CK: Cytokeratin; CDX2: Caudal-type homeobox 2; HER2: Human epidermal growth factor receptor 2; Li: Labeling index; HMB45: Human melanoma black 45.

RESULTS

The clinical diagnosis was based on the clinical examination of the breasts, so patients came for a consult with the surgeon either because they discovered a tumor formation in the breast, either were examined by the general practitioner and referred to the surgeon.

The tumor formation was detected following the local clinical examination (Fig. 1).

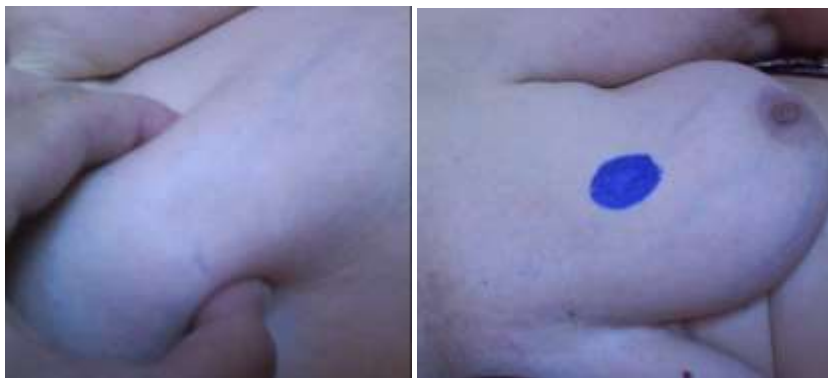

Figure 1. Palpable breast tumour (personal casuistry)

For the suspicion of breast tumor, the patients were examined by ultrasound and mammography (Fig. 2, 3).

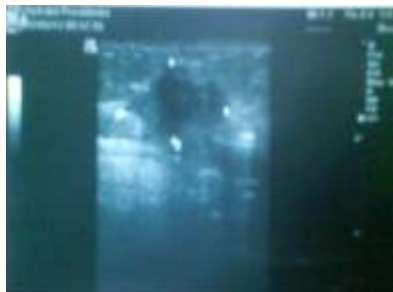

Figure 2. Breast ultrasound detects and measures the breast tumour (personal casuistry)



Figure 3. Mammography shows malignant tumours (personal casuistry)

Patients were informed of the high probability of having BC and agreed to undergo radical mastectomy surgery (Fig. 4) from the beginning.

All detected breast tumours were in the T3 stage N2-3 Mx with dimensions between 2 and 5 cm.

After rigorous preparation, surgery was performed by using a modified Madden radical mastectomy with axillary ganglion removal (Fig. 5, 6).

Aspiration drainage was used in all cases given the extent of dissection, and skin restoration (Fig.7) was facilitated by preoperative marking.

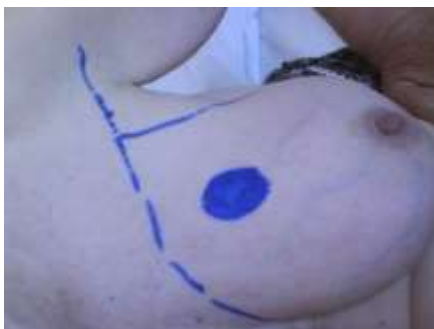

Figure 4. Preoperative marking
(personal casuistry)

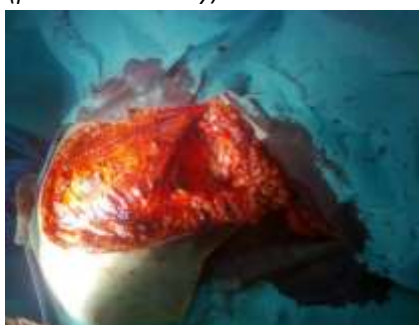


Figure 5. Axillary lymph node dissection

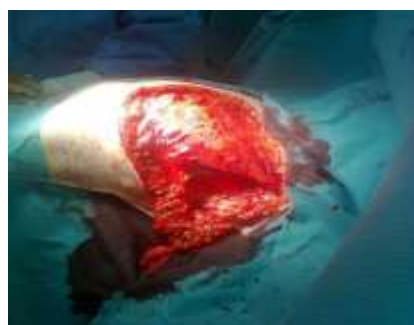

Figure 6. Large pectoralis muscle without poneurosis and armpit without lymph nodes

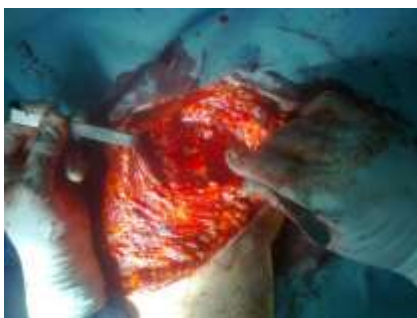

Figure 7. Axillary vein without lymph nodes

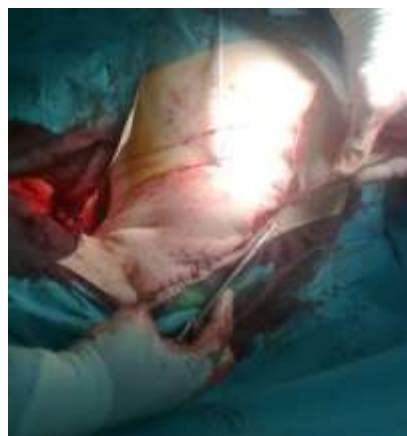

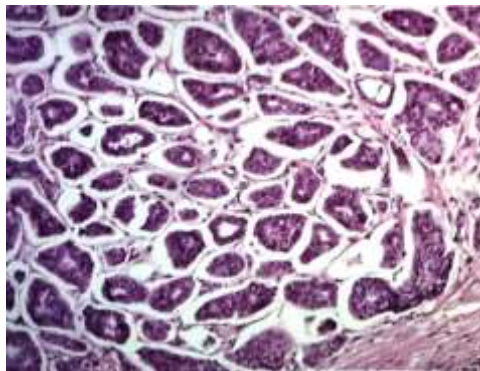
Figure 8. Skin suture

The removed body parts were sent for anatomopathological examination (Fig. 9).

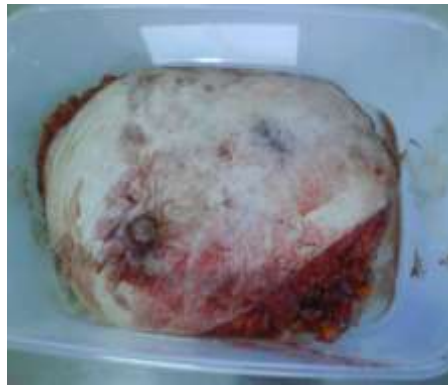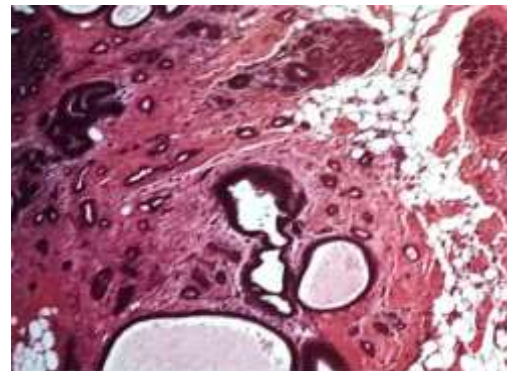


Figure 9. Excised body part
(personal casuistry)

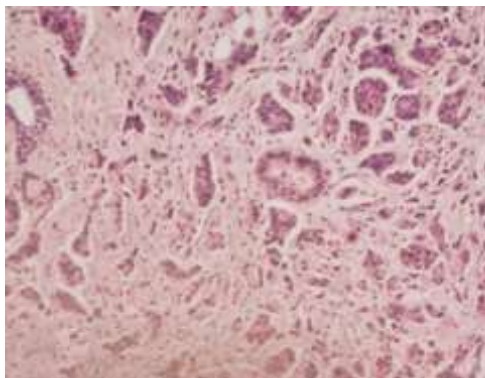
The microscopic pathological examination confirms the type of adenocarcinoma, the immuno-histochemical examination performed helping in this (Fig. 10 a,b,c,d).



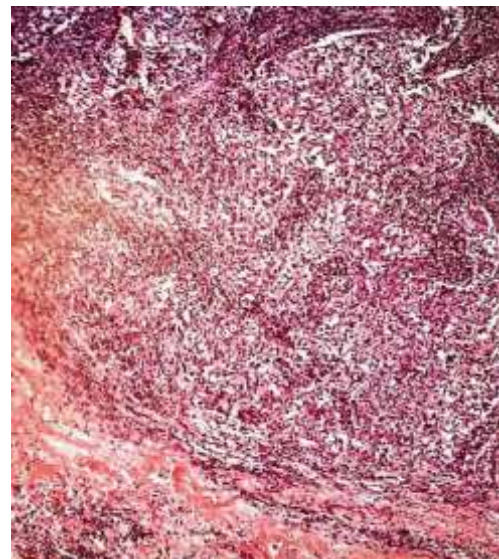
a) Invasive micropapillary carcinoma-pseudopapillae or tubules with inside outgrowth pattern. HE 400X OB 40x, Col HE, EPR 2764 Y. CK 20 +++



b) Tubular carcinoma- tubular structures with malign features invasive in adipose tissue. 400X, HE OB 40x, Col HE, KS 208, CK20 +++



c) Invasive breast carcinoma NOS- multiple tubular structures and desmoplastic stroma. 200X HE. OB 20x, Col HE, EPR 2764 Y, CDX2 +++



d) Tumour-infiltrating lymphocytes (Til) in invasive breast carcinoma. 200X HE OB 20x, Col HE, EPR 2764 Y, CK 20 +++

Figure 10. Immunohistochemistry.
(personal casuistry)

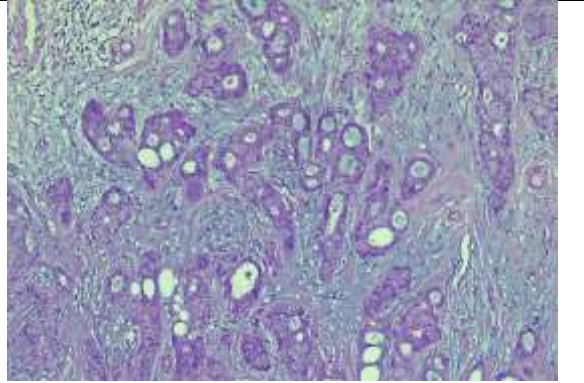
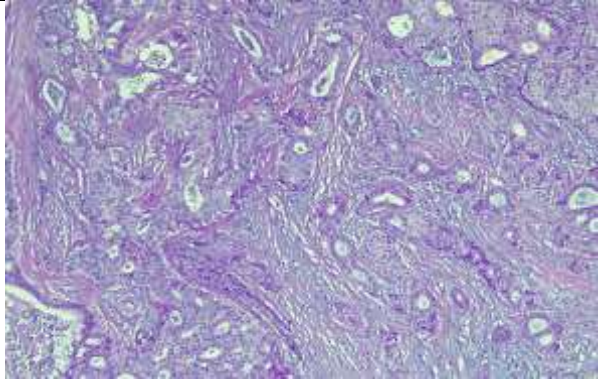
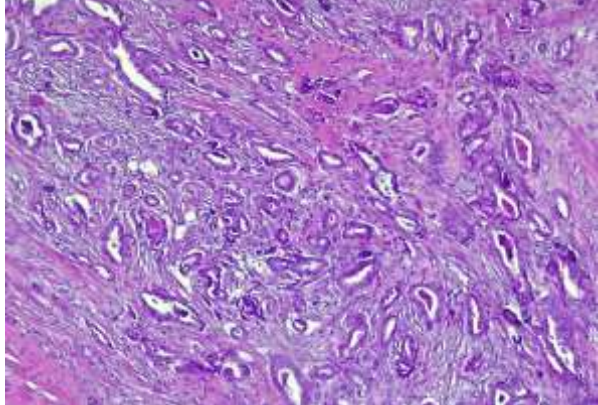
The Value of Clinical Anatomy, Imaging, Breast Gland Surgery and Therapeutic Implications in Breast Cancer

Vascular support of leukocyte trafficking in breast tumors and lymphatic invasion

Breast infiltrative leukocytes are described as complex pathways (traffic), engaging inputs through activated vascular endothelium (high endothelial venules type), more or less systematized pathways along the stromal connective fibers, either highlighted by short contact episodes of macrophages or other resident defense cells, or interrupted for decades by recirculation in relatively stable inflammatory structures possibly followed by lymphatic output to the drainage ganglia and then systemic dispersal (Fig. 11,a,b,c). Some of these steps can be suggested by the specific highlighting of the lesional blood and lymphatic vessels. Some of the signaling pathways controlling the passage of lymphocytes and dendritic cells from the tissue into the lymphatic efferents can also be found in some of neoplastic cells involved in lymphatic dissemination (inside vessels, placed in the lower part).

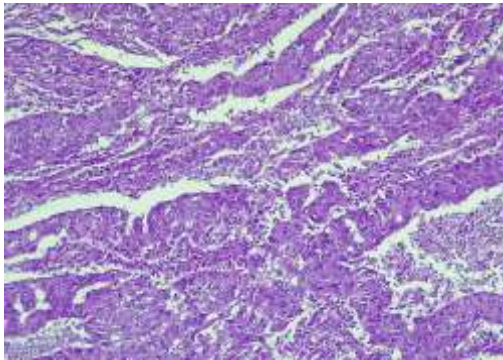
The next stage of approach was represented by the evaluation of the inflammatory infiltrate, from the point of view of the histoarchitectonics and its intensity and by means of the immunohistochemical markers that allow the identification of the cellular phenotype.

The methods used are based on current exploration resources (respectively, morphological examination in optical microscopy), which provides clues about **relations** but **does not validate the function**. These aspects are objective elements that support the hypothesis of the role of inflammatory infiltrate in the natural evolution of breast cancer, including through the intervention of the microenvironment in the development and, implicitly, the aggressiveness of the tumor.

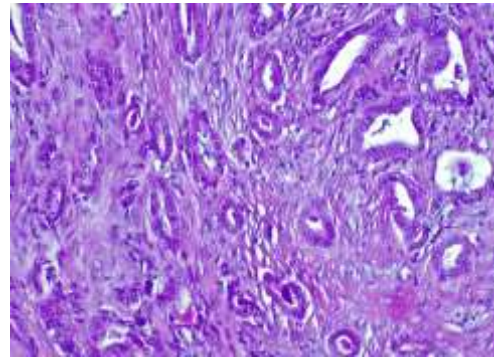
	
<p>a) F, 71 years-old- Moderately differentiated invasive tubular breast carcinoma – tumoral proliferation with < 75% tubular differentiation (HE x10), moderate nuclear pleomorphism, F: female, HE: Hematoxilin-Eosin, G2: moderately differentiated.</p>	<p>b) 67 years-old, F- Moderately differentiated invasive tubular breast carcinoma NOS – tumoral proliferation with <75% tubular differentiation (HEx10), moderate nuclear pleomorphism, F: female, NOS: not otherwise specific, HE: Hematoxilin-Eosin, G2: moderately differentiated.</p>
<p>Figure 11.a,b,c Exemples by invasive tubular brest carcinoma from our cases</p>	 <p>c) F, 71 years-old, Poorly differentiated invasive tubular breast carcinoma of no special type– tumoral proliferation with >75% tubular differentiation, reduced nuclear pleomorphism, multiple calcifications (HE x10). F: female, HE: Hematoxylin-Eosin, G1: well differentiated.</p>

The Value of Clinical Anatomy, Imaging, Breast Gland Surgery and Therapeutic Implications in Breast Cancer

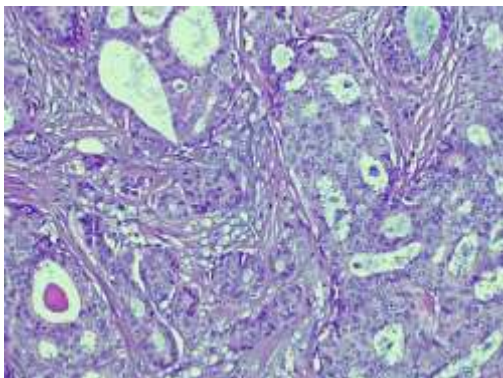
The results of this study (Fig. 12) show once again that the tumor follows a complex path that paradoxically gathers different types of relationships with the immune system and the rest of the body.



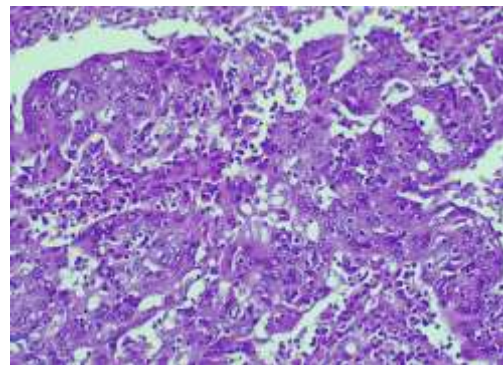
a) 68 years-old F, Poorly differentiated invasive tubular breast carcinoma NOS – tumoral proliferation with <10% tubular differentiation (HE x10) marked nuclear pleomorphism, F: female, NOS: not otherwise specific, HE: Hematoxilin-Eosin, G3: poorly differentiated.



b) 59 years-old F, Well-differentiated invasive tubular breast carcinoma NOS – tumoral proliferation with >75% tubular differentiation (HE x10) reduced nuclear pleomorphism, multiple microcalcifications, F: female, NOS: not otherwise specific, HE: Hematoxilin-Eosin, G1: well-differentiated.



c) Moderately differentiated invasive tubular breast carcinoma NOS – tumoral proliferation with <75% tubular differentiation (HE staining x20), moderate nuclear pleomorphism, NOS: not otherwise specific, HE: Hematoxilin-Eosin, G2: moderately differentiated.



d) Poorly differentiated invasive tubular breast carcinoma not otherwise specific – tumoral proliferation with <10% tubular differentiation (HE staining x20), marked nuclear pleomorphism, HE: Hematoxilin-Eosin, G3: poorly differentiated.

Figure 12.

The postoperative evolution was favorable, we did not have immediate postoperative complications.

Aspiration drainage was removed on average at 3 days. The mean length of hospital stay was 7 days. We can say that we had very good results after the elective operation performed. These were demonstrated by follow-up of cases performed by clinical control and CT 1 year after surgery (Fig. 13).

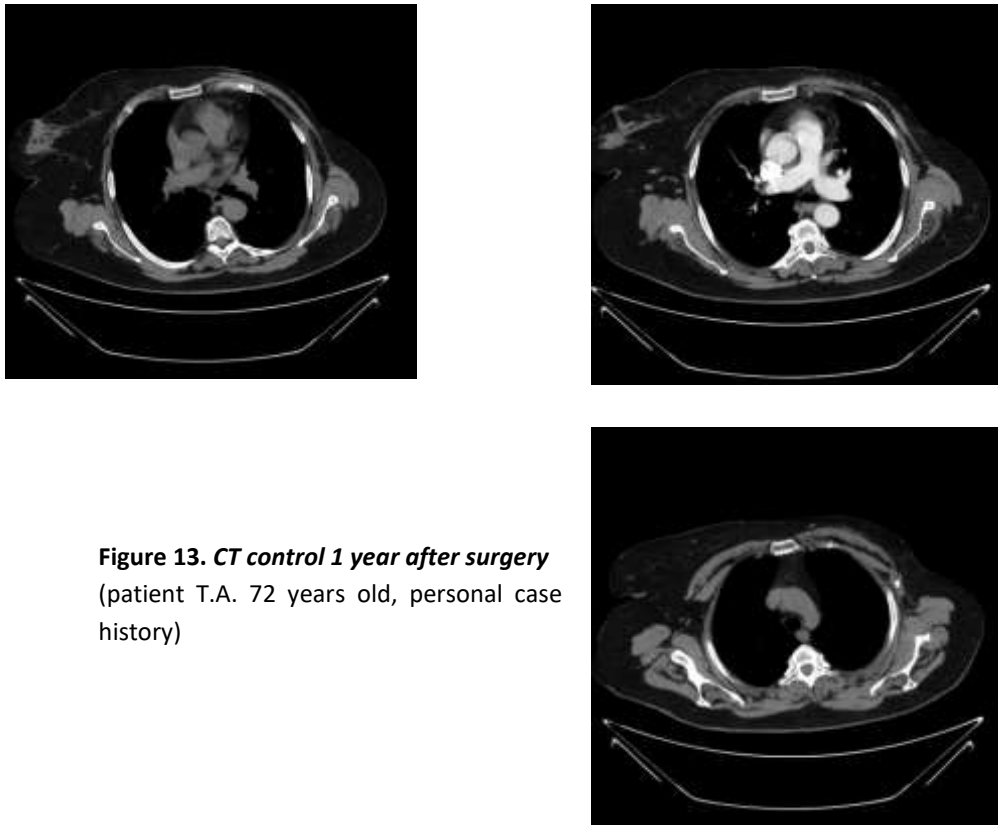


Figure 13. CT control 1 year after surgery
(patient T.A. 72 years old, personal case history)

DISCUSSIONS

The main technical problem solved by the original technique is the approach of the entire armpit (especially its tip) and the interpectoral ganglia (Rotter), thus allowing a complete cellulo-lymphadenectomy to be performed, "in sight", in block with the breast tumor. The method eliminates the known disadvantages of other surgical techniques, providing optimal conditions for axillary dissection by temporarily removing the pectoral muscles. This ensures a direct, wide, anterior approach, and the restoration of the muscular component of the anterior wall of the armpit, functional and protective against irradiation, directs healing by avoiding the appearance of arm edema.

It offers a satisfactory loco-regional radicalism from an oncological point of view because:

- Surgically removes the mammary gland, the adipose tissue around the breast, the skin over a large area, as well as the nearby fascial system with the preservation of the pectoral muscles; removes the primary tumor as well as any neighboring multiple subclinical foci, most of the lymph collectors, including the interpectoral ganglia, thus providing effective recurrence prophylaxis.
- Complete axillary lymphadenectomy allows microscopic control of all lymph nodes, avoiding false negative results; appreciation of the degree of invasion; positive lymph nodes removal, which exceed their ability -to overcome the defense capacity, become possible metastatic foci; correct staging of the disease; establishing a more accurate prognosis and the necessary complementary therapy.
- Respecting the principle of monobloc resection at a distance from the tumor reduces the risks of intraoperative dissemination. The intervention performed with ligature or harmonic scalpel is simple, fast, non-traumatic, well supported even by sicker patients.

Survival at 5 years is comparable to that in the literature [6], but qualitatively better and with satisfactory aesthetic results (offers favorable conditions for plastic reinterventions, in well-selected cases).

Breast cancer is a tumor with intermediate malignancy that recurs frequently and metastasizes. It mainly affects women over the age of 50.

Clinically the tumor can develop anywhere in the mammary gland but occurs more frequently in the superior-external quadrant. Diagnosis by microscopic anatomopathological examination and immunohistochemistry is mandatory and useful for further conduct. The anatomo-pathological results underlines the idea of the different behavior of the tumor cells [9], in a microenvironment in which they interfere with the components of the inflammatory infiltrate [10].

Based on the premise that in breast carcinomas there is an intense interaction between tumor cells on the one hand and

The Value of Clinical Anatomy, Imaging, Breast Gland Surgery and Therapeutic Implications in Breast Cancer

inflammatory cells, cytokines, chemokines [11], [12] and elements of the microenvironment on the other hand we tried to make morphological and biological correlations to answer the question: What is the relationship between biological markers of tumor aggression and inflammatory infiltrate?

Thus, the theory that the microenvironment has a crucial role in the development and evolution of breast cancer is increasingly confirmed [10], [13].

Metastases are most commonly located in the lungs or regional lymph nodes [14], [15], [16]. The incidence of recurrences and metastases is much higher in patients who are mistreated or initially treated incorrectly [17].

Mortality varies between 0-6% at 10 years after the first surgery and is relatively low [6], 0-1% in patients treated correctly [18], [19].

After the anatomopathological confirmation of the diagnosis [20], [21], the patients were referred to oncology for evaluation and continuation with adjuvant treatment

CONCLUSIONS

- The treatment of choice is surgical: excision of the tumor within the limits of oncological safety assessed by extemporaneous microscopic histopathological examination followed by re-excision if necessary.
- In the case of recurrences, a wide re-excision is performed with cell lymphadenectomy.
- Radiation therapy and chemotherapy may be combined postoperatively.
- In the case of late, metastatic tumors, surgical excision improves the prognosis by slowing the evolution of secondary tumors.
- Consensus points useful to clinicians: the potential for malignancy of any formation detected in a breast is a real risk.
- The possibility of a long asymptomatic period requires caution.
- Diagnostic errors negatively influence the evolution.
- **Proper surgical excision is the basic component of the treatment.** We did not opt in any case for enucleation, limited excision with anatomo-pathological examination or waiting for the intraoperative anatomo-pathological result because we had the informed consent of the patients from the preoperative period. Based on the clinical, mammographic and CT examination, the patients opted directly for radical surgery from the beginning.
- Postoperatively, the patient must be registered by the oncologist who will determine the therapeutic conduct adapted to each case.
- Detection of recurrences and long-term metastases after surgery requires long-term follow-up of patients.

CONFLICT OF INTERESTS

The authors declare that they have no conflict of interests.

REFERENCES

- 1) Clough K.B., Kaufman G.J., Nos C. *et al.* Improving breast cancer surgery: a classification and quadrant per quadrant atlas for oncoplastic surgery. *Ann Surg Oncol*, 2010; 17:1375-1391. DOI: 10.1245/s10434-009-0792-y.
- 2) Volovat C, Volovat S.R., Vulpoi C., Dascălu C.G., Cărauşu E.M. Quality of life of women receiving adjuvant hormonal treatment for breast cancer— a randomized trial comparing tamoxifen with aromatase inhibitors. *Jurnalul de Chirurgie, Iaşi*, 2011; 7(2): 193-202, [ISSN: 1584–9341].
- 3) Anastasiadi Z., Lianos G.D., Ignatiadou E., Harissis H.V., Mitsis M. Breast cancer in young women: an overview. *Updates Surg*, 2017; 69(3): 313-317. doi: 10.1007/s13304-017-0424-1.
- 4) Kolak A., Kamińska M., Sygit K., Budny A., Surdyka D., Kukiełka-Budny B., Burdan F. Primary, and secondary prevention of breast cancer. *Ann Agric Environ Med*, 2017; 24(4): 549-553. doi: 10.26444/aaem/75943.
- 5) Goldhirsch A., Wood W.C., Coates A.S., Gelber R.D., Thürlimann B., Senn H.J. Panel members. Strategies for subtypes— dealing with the diversity of breast cancer: highlights of the St. Gallen International Expert Consensus on the primary therapy of early breast cancer 2011. *Ann Oncol*, 2011, 22(8):1736–1747. <https://doi.org/10.1093/annonc/mdr304>; PMID: 21709140 PMCID: PMC3144634.
- 6) Siegel R.L., Miller K.D., Jemal A. Cancer statistics, 2020. *CA Cancer J Clin*, 2020; 70(1):7-30. doi: 10.3322/caac.21590.
- 7) Odle T.G. Precision Medicine in Breast Cancer. *Radiol Technol*, 2017; 88(4): 401M-421M. PMID: 28298516.
- 8) Fahad Ullah M. Breast Cancer: Current Perspectives on the Disease Status. *Adv Exp Med Biol*, 2019; 1152:51-64. doi:

The Value of Clinical Anatomy, Imaging, Breast Gland Surgery and Therapeutic Implications in Breast Cancer

10.1007/978-3-030-20301-6_4.

- 9) Partene Vicoleanu Simona Alice. Stromal inflammatory cell phenotypes in breast cancer. PhD thesis, "Grigore T. Popa" University of Medicine and Pharmacy, Iasi, Romania, prof. univ. dr. Carasevici Eugen, 2012.
- 10) Iancu G., Vasile D., Iancu R.C., Davițoiu D.V. "Triple positive" breast cancer—a novel category? *Rom J Morphol Embryol*, 2017, 58(1):21–26; PMID: 28523293.
- 11) Perou C.M., Sørli T., Eisen M.B., van de Rijn M., Jeffrey S.S., Rees C.A., Pollack J.R., Ross D.T., Johnsen H., Akslen L.A., Fluge O., Pergamenschikov A., Williams C., Zhu S.X., Lønning P.E., Børresen-Dale A.L., Brown P.O., Botstein D. Molecular portraits of human breast tumours. *Nature*, 2000, 406(6797): 747–752; <https://doi.org/10.1038/35021093>; PMID: 10963602.
- 12) Eliyatkin N., Yalçın E., Zengel B., Aktaş S., Vardar E. Molecular classification of breast carcinoma: from traditional, old-fashioned way to a new age, and a new way. *J Breast Health*, 2015, 11(2):59–66. <https://doi.org/10.5152/tjbh.2015.1669>; PMID: 28331693; PMCID: PMC5351488.
- 13) Volovat S., Apostol D., Volovat C., Cărașu M. Quality of Life of Women with Breast Cancer Treated in Adjuvant Setting with Tamoxifen or Aromatase Inhibitors. *European Journal of Cancer*, 2011; 47(Suppl. 1): S379. DOI: 10.1016/S0959-8049(11)71605-7.
- 14) Edge S.B., Sheldon D.G. Counterpoint: sentinel lymph node biopsy is not indicated for ductal carcinoma in situ. *J Natl Compr Netw*, 2003; 1:207-212. doi: 10.6004/jnccn.2003.0019.
- 15) Silverstein M.J., Lagios M.D., Groshen S. et al. The influence of margin width on local control of ductal carcinoma in situ of breast. *N Engl J Med* 1999; 340:1455-1461.
- 16) Hashmi A.A., Aijaz S., Mahboob R., Khan S.M., Irfan M., Iftikhar N., Nisar M., Siddiqui M., Edhi M.M., Faridi N., Khan A. Clinicopathologic features of invasive metaplastic and micropapillary breast carcinoma: comparison with invasive ductal carcinoma of breast. *BMC Res Notes*, 2018, 11(1):531. <https://doi.org/10.1186/s13104-018-3623-z> PMID: 30064485 PMCID: PMC 6069771.
- 17) Chen A.C., Paulino A.C., Schwartz M.R., Rodriguez A.A., Bass B.L., Chang J.C., Teh B.S. Population-based comparison of prognostic factors in invasive micropapillary and invasive ductal carcinoma of the breast. *Br J Cancer*, 2014, 111(3): 619–622. <https://doi.org/10.1038/bjc.2014.301>; PMID: 24921921; PMCID: PMC 4119976.
- 18) Baucom D.H., Porter L.S., Kirby S.J. et al. Psychosocial issues confronting women with breast cancer. *Breast Dis* 2005; 23:103-113. doi: 10.3233/bd-2006-23114.
- 19) Arrigada R., Le W.G., Rochard F., Contesso G. Conservative treatment versus mastectomy in early breast cancer: patterns of failure with 15 years of follow-up data. Institute Gustave Roussy, Brest Cancer Group. *J Clin Oncol*, 1996; 14(5):1558-1564. doi: 10.1200/JCO.1996.14.5.1558.
- 20) Litière S., Werutsky G., Fentiman I.S., Rutgers E., Christiaens M.R., Van Limbergen E., Baaijens M.H., Bogaerts J., Bartelink H. Breast conserving therapy versus mastectomy for stage I-II breast cancer: 20 years of follow-up of the EORTC 10801 phase 3 randomised trial. *Lancet Oncol*, 2012; 13: 412-419. doi: 10.1016/S1470-2045(12)700 42-6.
- 21) Cărașu M., Bidard F.C., Callens C., Melaabi S., Jeannot E., Pierga J.Y., Cabel L. ESR1 mutations: a new biomarker in breast cancer. *Expert Rev Mol Diagn*. 2019; 19(7):599-611. doi: 10.1080/ 14737159.2019.1631799; PMID:31188645.



There is an Open Access article, distributed under the term of the Creative Commons Attribution – Non Commercial 4.0 International (CC BY-NC 4.0) (<https://creativecommons.org/licenses/by-nc/4.0/>), which permits remixing, adapting and building upon the work for non-commercial use, provided the original work is properly cited.