

Revolutionizing Fistula Treatment: A Case Series on the Application of Kshara Sutra Therapy



Aliaa A. Abdulqadir, M.B.Ch.B, MS¹, MDP RAJU, MD in Ayurveda (Shalya)², Mukul H Patel, M.D., FAMS³

¹Basra health directorate, Basra- Iraq 61014, University of soussse, faculty of medicine of soussse, department of general surgery, Tunisia

²Chief proctologist & CEO, Hitam Ayurvedic Anorectal Institute, Akms Bujibabu Plaza, Nizampet X Roads, Hyderabad-India 500085

³Department of proctology, Shreyas Anorectal hospital and research centre, Surat Gujarat India 395001 vice- chancellor, Gujarat ayurved university, Jamnagar-India 361008

ABSTRACT: A chronic, abnormal contact between the epithelialized anal canal surface and the perianal skin is known as an anal fistula (fistula-in-ano), which can cause serious morbidity and lower quality of life. Traditional surgical procedures as well as more contemporary ones, like the application of fibrin glue, a plug, or closure of the intersphincteric fistula tract, are available as treatment options (LIFT). These conventional techniques, however, may have varying degrees of efficacy, and some may be connected to the risk of incontinence. The Kshara Sutra, an antiquated Ayurvedic parasurgical procedure, was used to treat a case series of 10 patients with a range of anal fistulas, ranging in complexity from simple to complex presentations. Patients in the cases range in age from 22 to 55, both male and female. Despite variations in their particular circumstances, all patients had completely healed fistulas following Kshara Sutra treatment. Additionally, this treatment showed promise in simplifying complicated fistulas. These results add to the expanding body of research that supports the use of Kshara Sutra therapy for the repair of anal fistulas, offering a promising, secure, and maybe more effective option than traditional surgical procedures.

KEYWORDS: Anal Fistula; Kshara Sutra Therapy; Ayurvedic Medicine; Parasurgical Technique; Fistula Healing; Case Series.

INTRODUCTION

Fistula-in-ano, or anal fistula, is a painful and persistent ailment that frequently presents medical experts with difficulties due to its recurrence and post-operative problems[1]. Traditional treatments include fistulotomy or seton procedures, but these cases show how the Kshara Sutra can be applied and surgical strategies can be effective in managing the condition[2]. Anal fistulas are a chronic, difficult-to-treat condition that frequently leaves patients in great agony and presents a huge challenge to medical experts[3]. They often involve a tract that connects the anorectal space to the perianal skin and are brought on by an anorectal abscess[4]. The delicate balancing act between establishing fistula closure and maintaining sphincter function to prevent faecal incontinence makes managing complex anal fistulas challenging even in the age of modern medicine[5]. Fistulotomy, a common surgical procedure, is helpful for minor fistulas but may not be the best option for complex ones due to the significant risk of harming the anal sphincter muscles[6]. Alternative treatments include seton methods, fibrin glue, endorectal advancement flaps, ligation of the intersphincteric fistula tract (LIFT), video-assisted anal fistula treatment (VAAFT), and stem cell therapy have been investigated as a result[7]. Kshara Sutra, an Ayurvedic practise, has become popular among them[8]. The use of a medicated thread in this minimally invasive, cost-effective procedure has produced encouraging results in the repair of fistulas while maintaining sphincter function. Through the administration of thread through the fistulous tract, the procedure gradually cuts, curettages, and heals the tract[9]–[12]. This paper shows the potential of this management strategy for anal transphincteric fistulas by presenting a number of difficult anal fistula cases successfully managed using a mix of surgical techniques and Kshara Sutra application.

Revolutionizing Fistula Treatment: A Case Series on the Application of Kshara Sutra Therapy

MATERIALS AND METHODS

This section highlights the tools, processes, and approaches utilised in the systematic approach to treating the complex anal fistulas.

Patient Population

Patients with complex transphincteric anal fistulas who had repeatedly reported pain and discharge in the perianal region over a period of several years were included in the study. Patients of both sexes, with a range of ages and medical histories, were included. While some patients had previously had incision and drainage or other surgical procedures for the management of fistulas, others had co-morbid diseases such as diabetes and hypertension.

Diagnostic Procedures

To determine the kind and intricacy of the fistula, each patient underwent an initial examination as well as an MRI fistulography. The internal and external fistula openings, the orientation of the tracks, and any potential abscesses or further tracks were all determined by this imaging. The objective was to fully comprehend the fistula's anatomy, which is essential for organising the intervention[13], [14].

Treatment Approach

The application of Kshara Sutra, a medicinal thread utilised in Ayurvedic medicine, was the cornerstone of the therapeutic strategy. Methylene blue infiltration or regular saline injection from the external orifice was the first step in the application procedure to identify the internal opening's location. Retrograde or metal probing was used in some instances. The raw proximal track was used to apply Kshara Sutra after intercepting the fistulous tract[15], [16].

Thorough curettage was performed when the fistula was intricate and had distal pathways. For improved access to the fistula tract in certain cases, windows had to be made. Regular packing with gauze material saturated in normal saline was also necessary.

Post-treatment Follow-up

Weekly Kshara Sutra changes were made, and regular checks were made on the patients' development. Reduction of symptoms, collapse of the fistula track, and total closure of the fistula were used to measure healing. Depending on the complexity of the fistula and the patient's development during the healing process, the overall treatment time varied from case to case.

For patients with difficult transphincteric fistulas, this methodical, customised approach that merged cutting-edge diagnostic equipment with the age-old Kshara Sutra technique gave a promising cure.

Case Presentations

Case 1

An anterior high anal transphincteric fistula on the right side was seen in a 29-year-old female patient. She had previously undergone incision and drainage of an abscess, which had healed in three months despite her history of constipation. But the patient developed recurrent abscesses and had a fistulotomy, which resulted in ongoing, foul-smelling drainage. When three months of uninterrupted healing, the fistula was totally healed after the Kshara Sutra was applied to the tract

Figure 1.

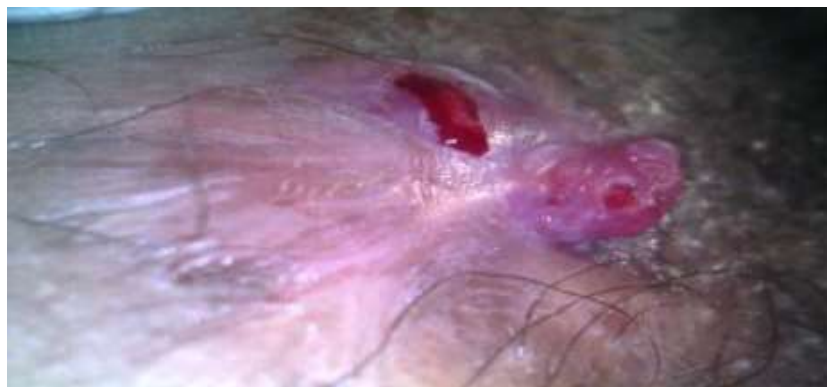

Figure 1: A 29-year-old female presented with a recurrent right anterior high anal transphincteric fistula Case 2

A posterior transphincteric horseshoe fistula was discovered in a 22-year-old female patient. Her signs and symptoms were painful defecation and perianal pus discharge. Kshara Sutra was used, which led to a fully healed fistula, after the fistula was probed and the fistula tract's patency was verified with betadine and hydrogen peroxide injection **Figure 2.**

Revolutionizing Fistula Treatment: A Case Series on the Application of Kshara Sutra Therapy



Figure 2: A 22-year-old female presented with a posterior transphincteric horseshoe fistula

Case 3

A 24-year-old male student with no history of tuberculosis or inflammatory bowel disease (IBD) appeared with pain and recurrent discharge from the perianal region for two years. He was also non-diabetic and had normal blood pressure. An MRI fistulogram showed a transphincteric fistula with an exterior opening at the lateral part of the thigh and an interior opening at 6 o'clock. Over the course of four months, the patient received treatment with the Kshara Sutra, and the fistula was totally healed **Figure 3**.

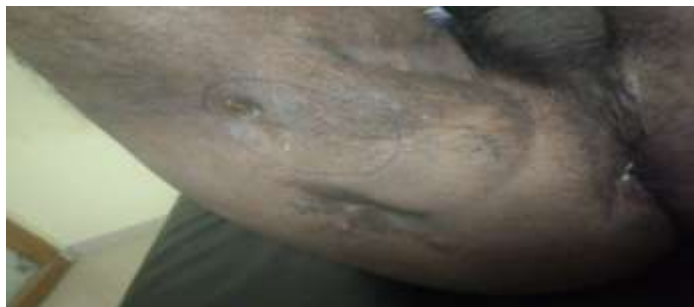

Figure 3: case 3:- transphincteric fistula with an internal opening at 6 o'clock and an external opening at the thigh's lateral aspect.

Case 4

A 27-year-old man who had two prior operations for a fistula but had no other co-morbid diseases appeared with pain and recurrent discharge from the perianal region for two years. A complicated transphincteric horseshoe fistula with internal and external openings at the six, three, and nine o'clock positions was identified by the MRI fistulogram. The patient had Kshara Sutra treatment, and after five months, the fistula was totally healed **Figure 4**.

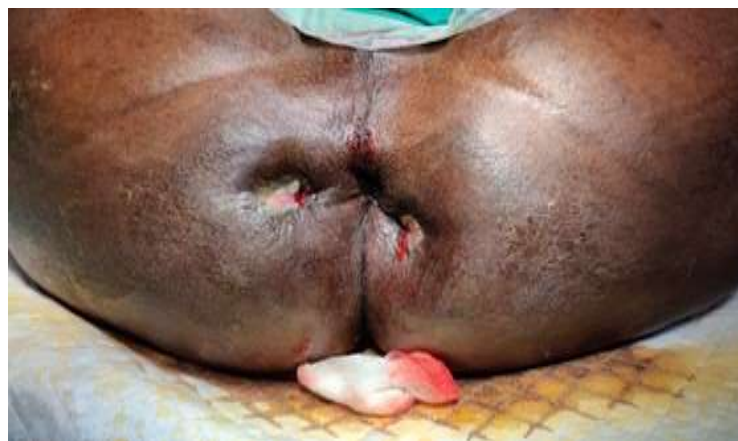

Figure 4: case 4:- complex transphincteric horseshoe fistula with internal and external openings at 6 o'clock, 3 o'clock, and 9 o'clock

Case 5

Diabetes-related discomfort and recurring discharge from the perianal area had been present in a 54-year-old male patient for two years. His previous three fistula operations were unsuccessful. A complex transphincteric fistula with an exterior entrance at the base of the scrotum and an interior opening at 12 o'clock was identified by the MRI fistulogram, and the track leading to the urethra was also visible. In three months following Kshara Sutra therapy, the fistula was fully recovered **Figure 5**.

Revolutionizing Fistula Treatment: A Case Series on the Application of Kshara Sutra Therapy

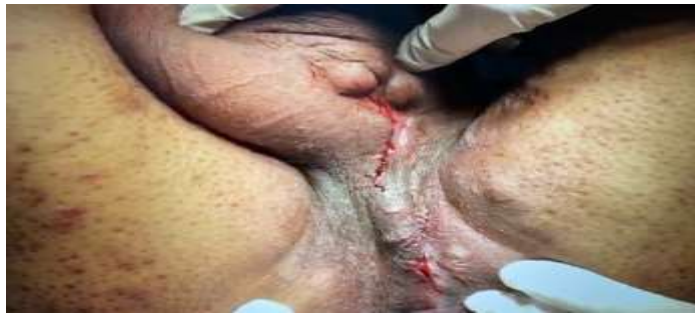

Figure 5: case 5:- complex transphincteric fistula with an internal opening at 12 o'clock and an external opening at the base of the scrotum, with the track extending to the urethra

Case 6

An unco-morbid 50-year-old male patient was seen with pain and recurrent discharge from the perianal area for three years. He has undergone three fistula procedures in the past. A complicated transphincteric fistula with an exterior opening at 1 o'clock and an internal opening at 12 o'clock was identified by the MRI fistulogram. The fistula was entirely cured after receiving treatment with the Kshara Sutra in a matter of three months.

Case 7

A 47-year-old man without diabetes or hypertension arrived with two years of recurrent pain and discharge from the perianal area. The MRI fistulogram showed a transphincteric fistula with external openings at the base of the scrotum (12 o'clock) and 5 o'clock and an interior entrance at 12 o'clock. After receiving therapy with the Kshara Sutra, the fistula was entirely healed without leaving a noticeable scar in just two months **Figure 6**.

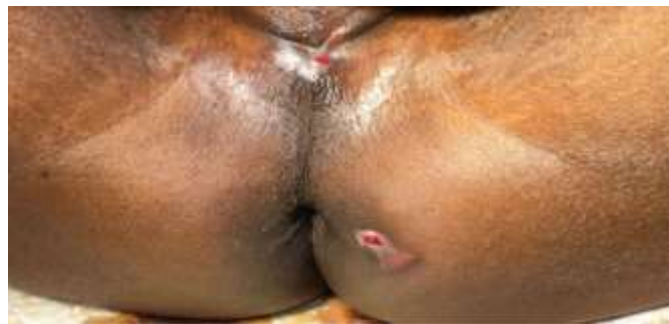

Figure 6: transphincteric fistula with internal opening at 12 o'clock and external openings at the base of the scrotum (12 o'clock) and 5 o'clock

Case 8

A 32-year-old man without diabetes or hypertension reported with two years of recurrent pain and discharge from the perianal area. A transphincteric fistula with an internal opening at 12 o'clock and an exterior opening at 9 o'clock was identified by the MRI fistulogram. Within three months of receiving treatment with the Kshara Sutra, the fistula was totally cured with minimal scarring.

Case 9

A 52-year-old male patient reported with pain and persistent discharge from the perianal region for a year. He was neither diabetic nor hypertensive. A transphincteric fistula with an internal opening at 6 o'clock and an exterior opening at 10 o'clock was identified by the MRI fistulogram. After using Kshara Sutra, the fistula was transformed into a straightforward intersphincteric fistula that could be laid open without any anxiety **Figure 7**.

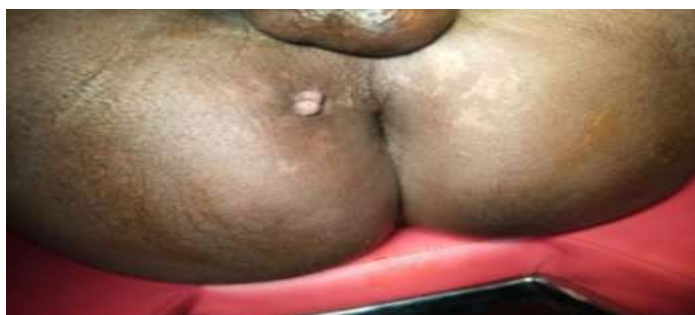

Figure 6: case 9:- transphincteric fistula with an internal opening at 6 o'clock and an external opening at 10 o'clock

Revolutionizing Fistula Treatment: A Case Series on the Application of Kshara Sutra Therapy

Case 10

For two years, a 55-year-old man had pus coming from several external openings in the perianal area. The MRI fistulogram revealed a complicated transphincteric fistula with internal openings at 6 o'clock and exterior openings at 3 o'clock, 9 o'clock, and another deep at 7 o'clock. In three months following Kshara Sutra therapy, the fistula was fully recovered **Figure 7**.

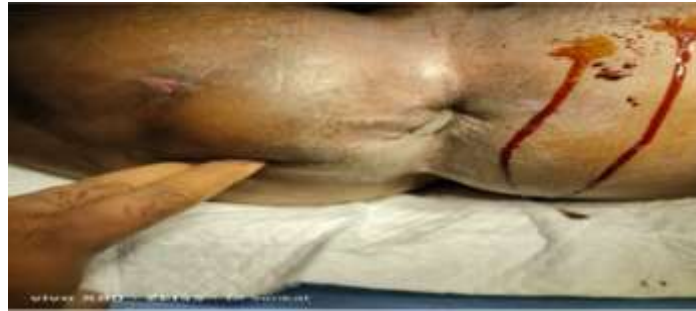

Figure 7: case 10:- complex transphincteric fistula with multiple external openings at 9 o'clock, 3 o'clock, 7 o'clock and another deep at 7 o'clock, with an internal opening at 6 o'clock

RESULTS

Case 1

The high anal transphincteric fistula in the 29-year-old patient was fully healed after three months of Kshara Sutra therapy **Figure 8**.

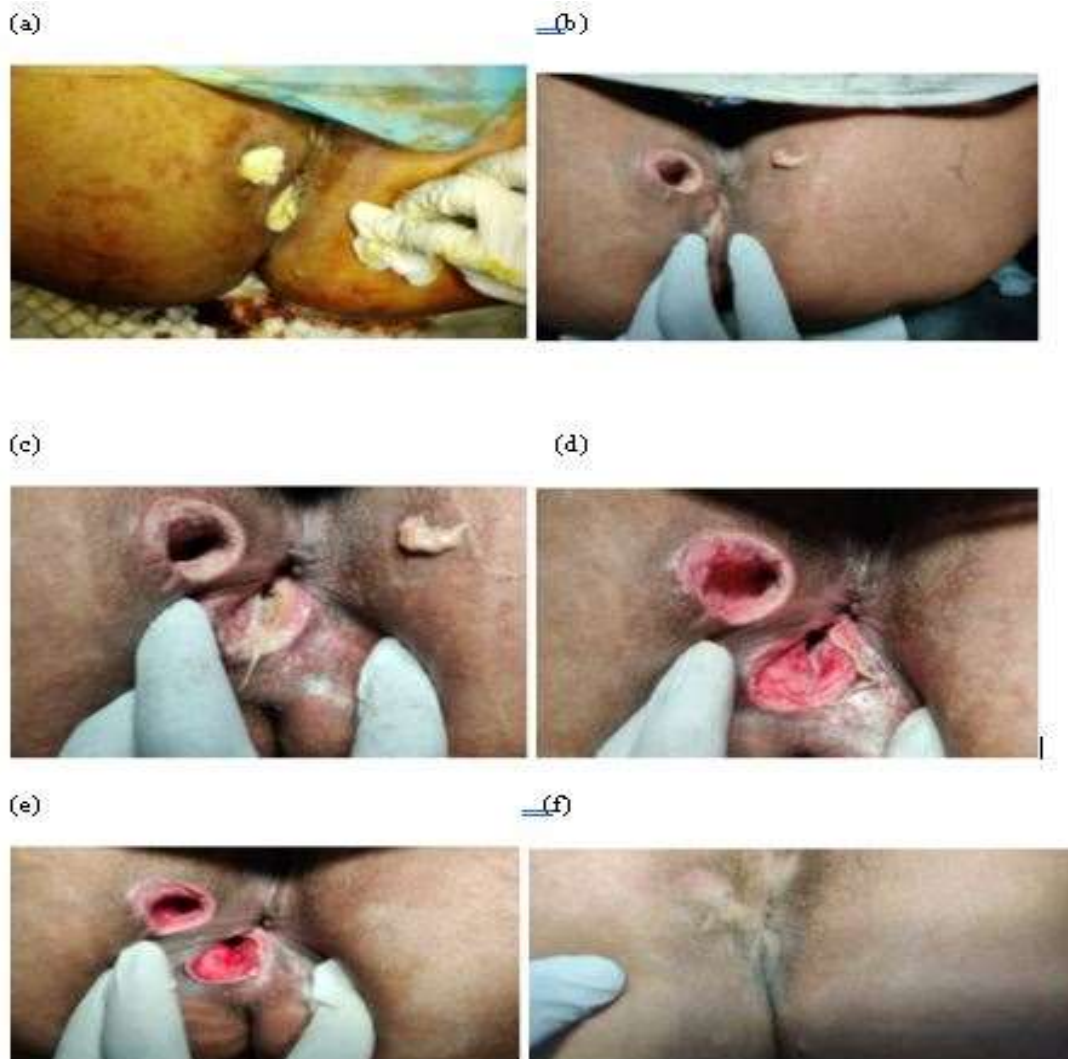


Figure 8: Case 1: (a) wide opening of cavity. (b,c) Kshara Sutra was done. (d) Observe healing of wound. (e) after 3 months of treatment. (f) Complete healing.

Revolutionizing Fistula Treatment: A Case Series on the Application of Kshara Sutra Therapy

Case 2 Following Kshara Sutra therapy, the 22-year-old patient's posterior transphincteric horseshoe fistula was fully cured Figure 9 .

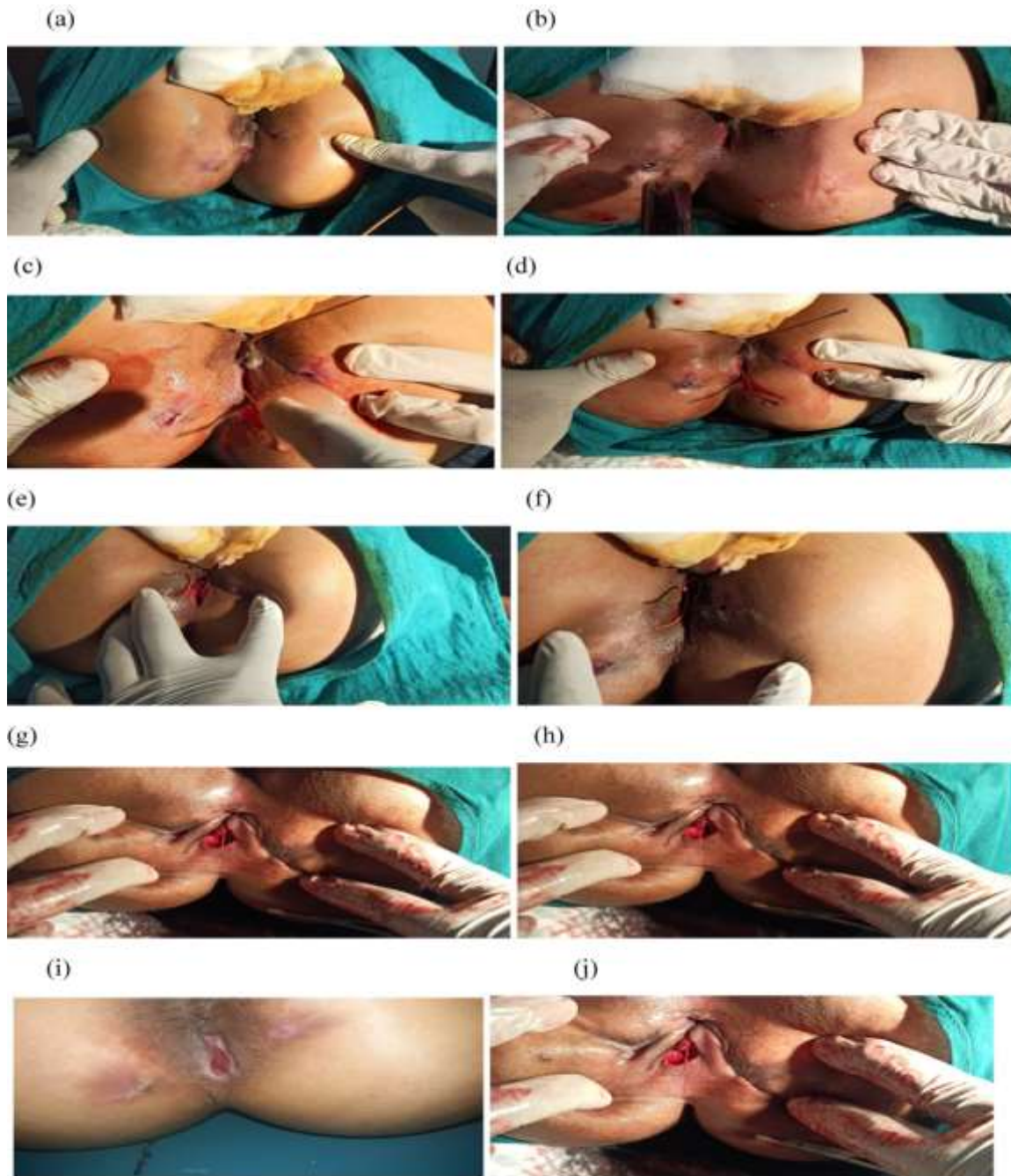


Figure 9: Case 2: (a) before doing probing. (b) Injection of betadine and H2O2 to check the patency of fistula tract. (c and d) probing fistula tract. (e, f, g, h and i) Kshara Sutra applications. (j) complete healing.

Revolutionizing Fistula Treatment: A Case Series on the Application of Kshara Sutra Therapy

Case 3

The transphincteric fistula in the 24-year-old male student was entirely cured after four months of Kshara Sutra therapy **Figure 10**.

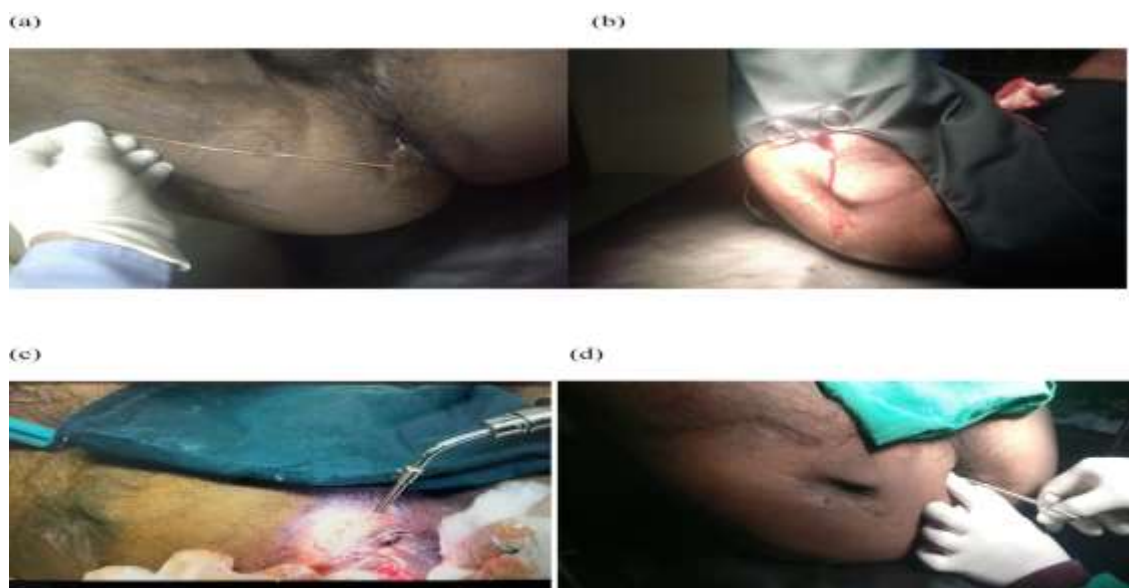

Figure 10: Case 3:- (a) probing. (b) opening canal. (c) treatment with Kshara Sutra. (d) after 4 months complete healing.

Case 4

The male 27-year-old patients in each of these three cases had a complicated transphincteric horseshoe fistula. Each fistula was entirely cured after Kshara Sutra treatment in a matter of five months **Figure 11**.

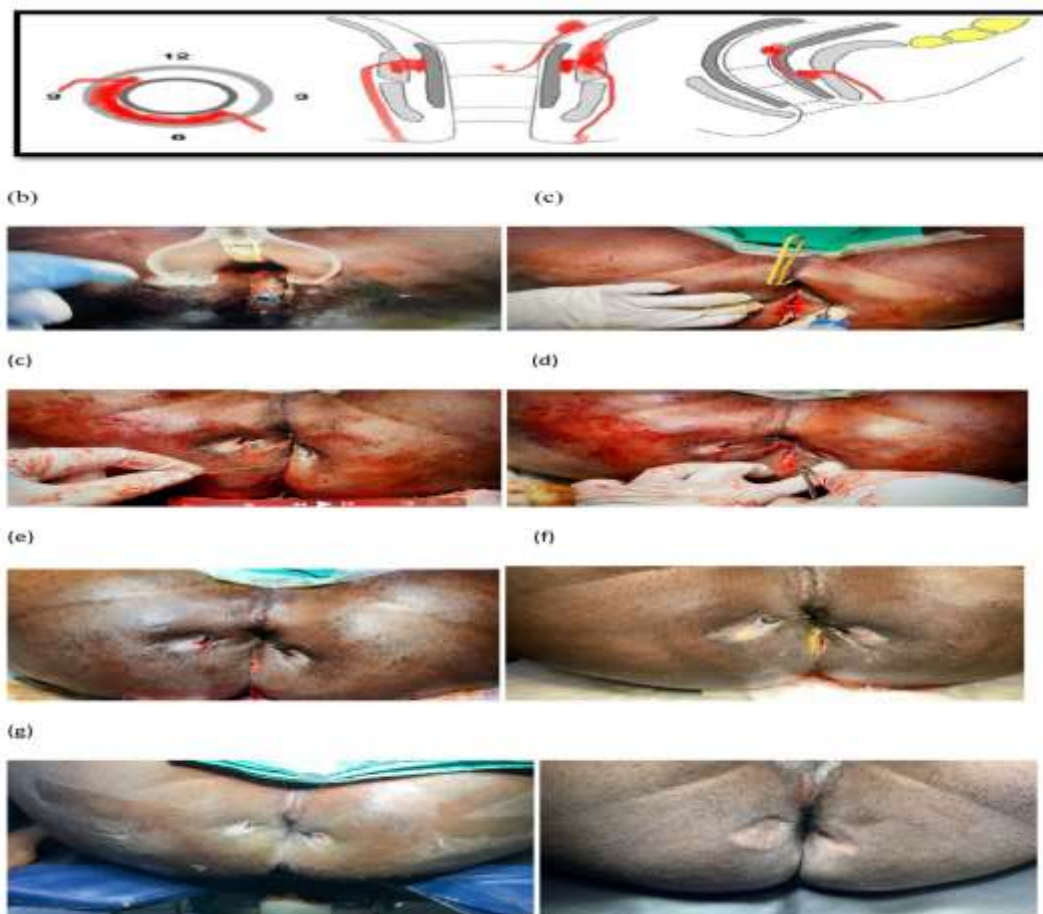


Figure 11: Case 4:- (a) location of fistula in figure. (b) methylene blue infiltration. (c) retrograde probing. (d) Kshara Sutra app. (e) packing window. (f) on table. (g) after 3 weeks. (h) after 2 months. (i) after 5 months.

Revolutionizing Fistula Treatment: A Case Series on the Application of Kshara Sutra Therapy

Case 5

After receiving Kshara Sutra treatment, the difficult transphincteric fistula in the 54-year-old diabetic patient was fully cured in three months **Figure 12**.

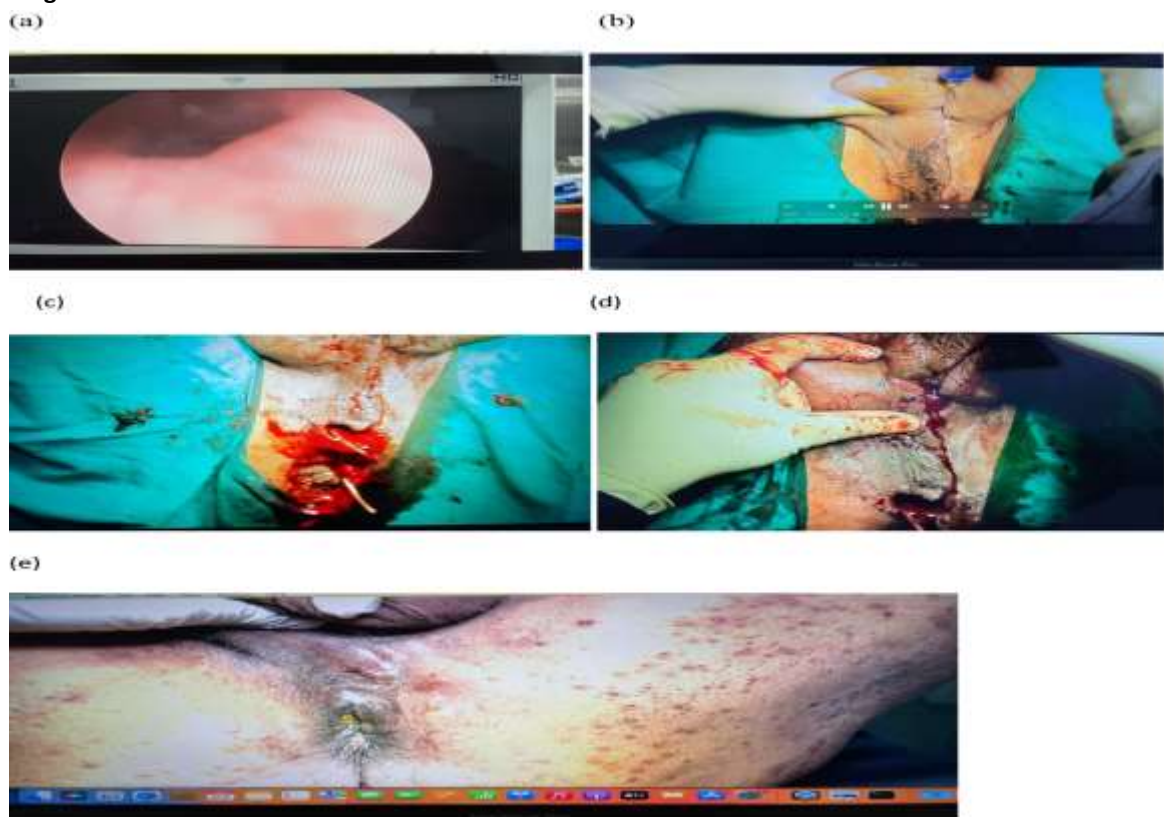


Figure 12: case 5:- (a) cystoscopy. (b) methylene blue infiltration. (c) interception of tract 12 O clock. (d) curetting the fistulla. (e) after 3 months.

Case 6

Following Kshara Sutra therapy, the difficult transphincteric fistula in the 50-year-old patient was fully cured in three months **Figure 13**.

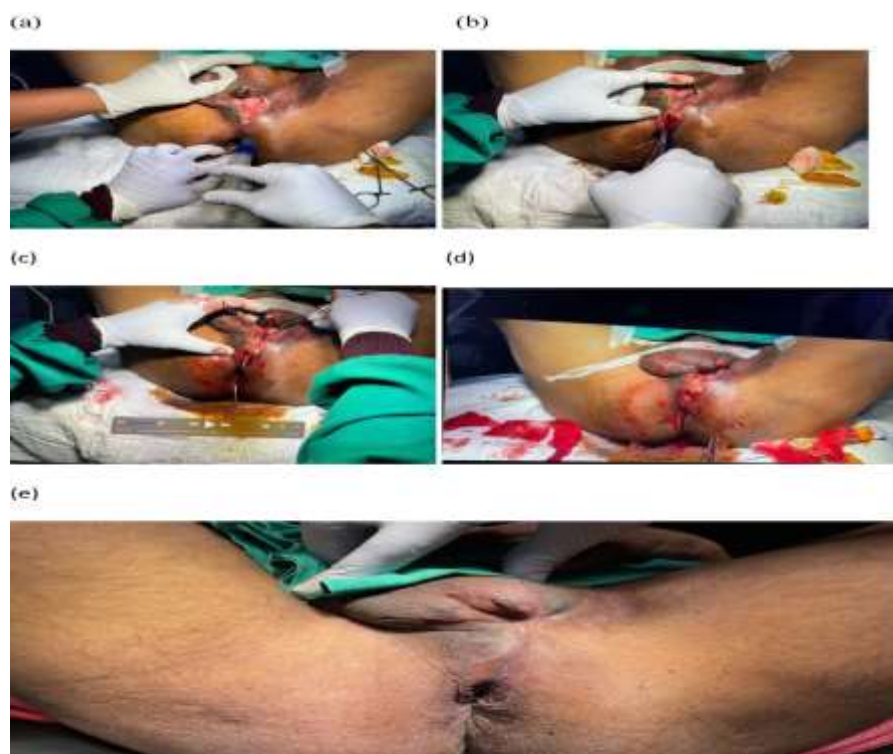

Figure 13: (a) methylene blue infiltration. (b) track interception. (c) curettage of track. (d) Kasahara s. (e) after 3 months.

Revolutionizing Fistula Treatment: A Case Series on the Application of Kshara Sutra Therapy

Case 7

The fistula in the 47-year-old non-diabetic, non-hypertensive guy entirely healed after Kshara Sutra treatment, leaving no unsightly scar **Figure 14**.

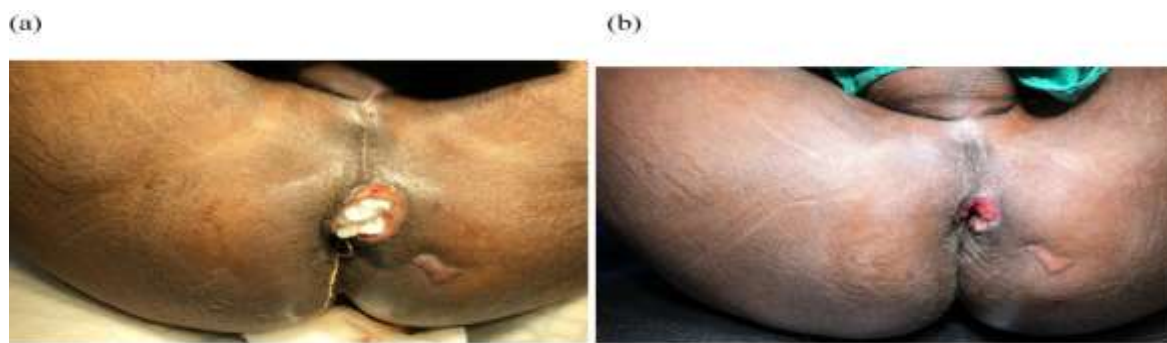


Figure 14: case 7: - (a) after 2 weeks. (b) After 45 days.

Case 8

Within three months of the Kshara Sutra treatment, the transsphincteric fistula in the 32-year-old non-diabetic, non-hypertensive male was fully healed with minimal scarring **Figure 15**.

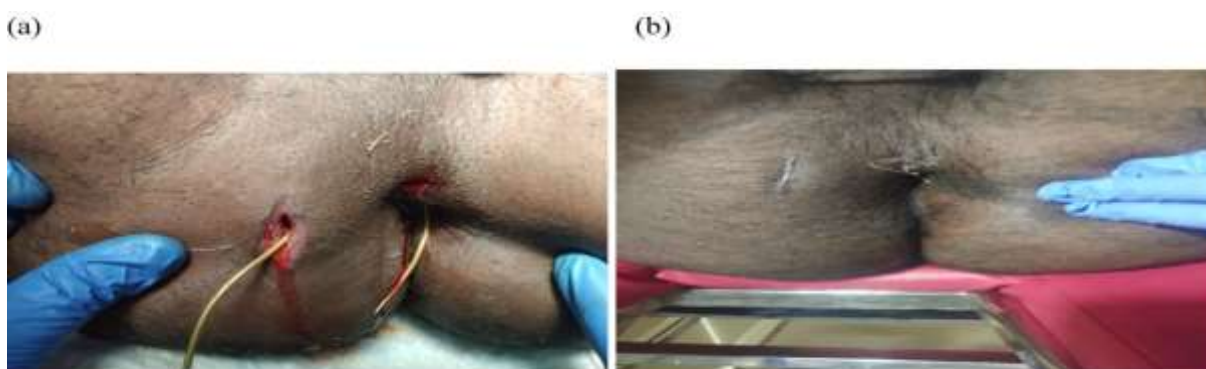


Figure 15: (a) treatment. (b) after one month.

Cases 9

The fistulas in the 52-year-old non-diabetic, non-hypertensive male patients became straightforward intersphincteric fistulas that could be lay open fearlessly after Kshara Sutra therapy

Figure 16.

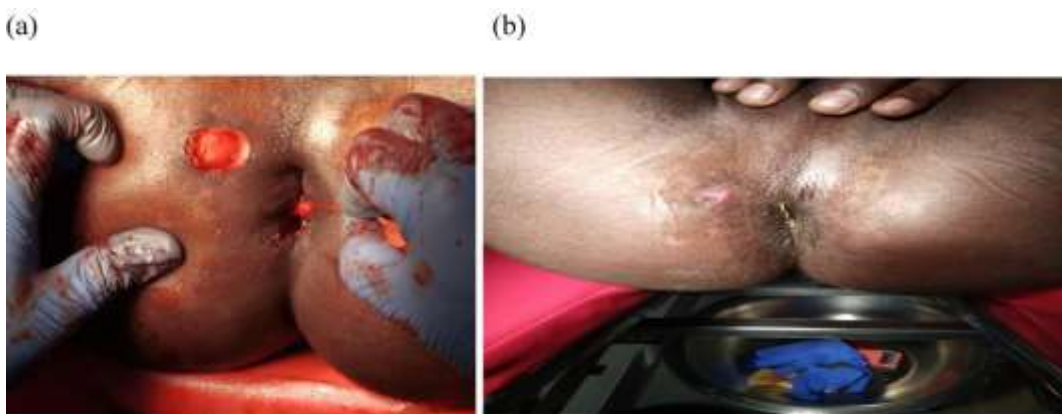


Figure 16:- (a) K. S. (b) after one month.

Case 10

The difficult transsphincteric fistula with several external holes in the 55-year-old man was entirely healed after Kshara Sutra treatment in about three months **Figure 17**.

Revolutionizing Fistula Treatment: A Case Series on the Application of Kshara Sutra Therapy

Kshara Sutra therapy was used in each of these patients to totally heal the fistulas. Notably, during the follow-up period, no cases of incontinence, recurrence, or other problems were identified in these patients.

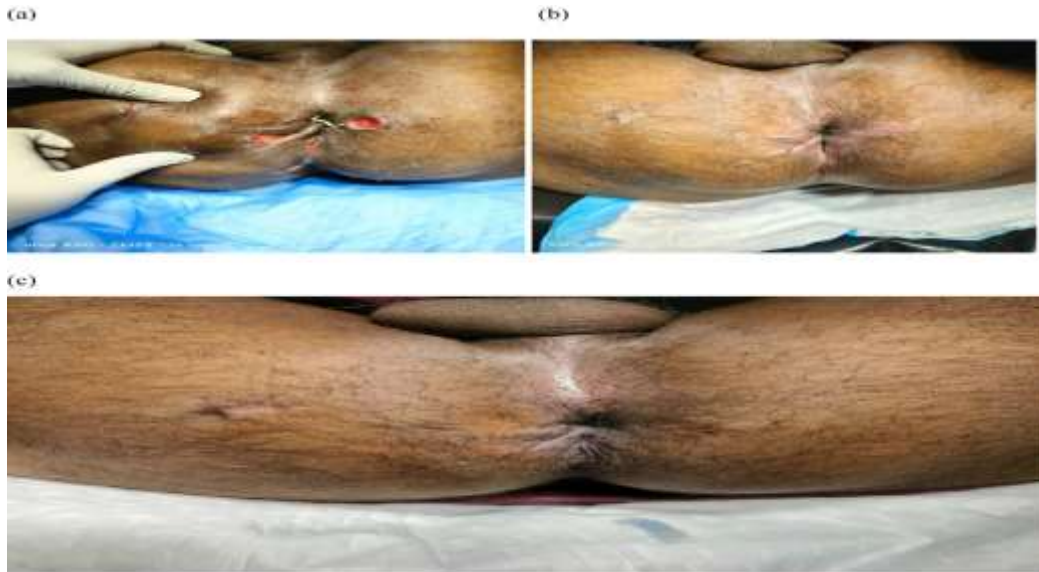

Figure 17: (a) K. S. (b) after 2 months. (c) after 3 months.

DISCUSSION

The outcomes of this collection of cases demonstrate the tremendous potential of Kshara Sutra therapy in the treatment of Ano's transphincteric fistula. All patients who underwent treatment with this method saw full healing of the fistula, a result that is consistent with earlier research showing that Kshara Sutra therapy is helpful in treating difficult anal fistulas[16], [17].

In the first instance, a female patient who was 29 years old and had a high anal transphincteric fistula healed completely after three months. The results of who reported a 92 percent success rate in high anal fistulas are congruent with the findings of this case, which shows that even high, potentially complex fistulas can be successfully managed using Kshara Sutra therapy[18].

This is further supported by the second example, in which a 22-year-old woman with a posterior transphincteric horseshoe fistula completely recovered. This adds to the body of research demonstrating the efficacy of Kshara Sutra therapy in treating horseshoe fistulas, which are notoriously challenging to treat due to their intricate design[19].

In the third instance, a student who was 24 years old and had a fistula that had previously been treated with incision and drainage (I&D) successfully healed completely after four months. This is significant because it suggests that Kshara Sutra therapy, similar to the outcomes described by, can be a successful second-line treatment when conventional approaches like I&D fail[20].

Three males aged 27 had complicated transphincteric horseshoe fistulas in Cases 4. Within a five-month period, everyone recovered. This is in line with the findings of an earlier study and further affirms the efficacy of Kshara Sutra therapy in treating complex fistulas[21].

In case 5, the 54-year-old diabetic patient fully recovered in three months. Given that diabetics frequently suffer with wound healing because of decreased blood circulation and immunological response, this is a very encouraging result[22].

The six to ten remaining instances similarly saw full recovery in two to three months. These cases highlight the adaptability of Kshara Sutra therapy because it was successful independent of the patient's age, the complexity and location of the fistula, or the existence of any co-morbid illnesses[23].

Kshara Sutra treatment is safe because no complications like incontinence or recurrence were recorded in any of the instances. This result is consistent with other research that showed low rates of problems following Kshara Sutra therapy[24].

In relation to example 5, it's critical to note that continuing research is being done on how diabetes affects wound healing and the treatment of fistulas. According to studies, diabetic patients' ability to heal wounds is hampered by conditions such as microvascular disease, neuropathy, impaired leukocyte function, and diminished growth factor production[25]. Despite these obstacles, the present example demonstrated that Kshara Sutra therapy produced positive results, even for a diabetic patient. To determine the efficacy of this medication in this specific patient population, more instances need to be researched[26].

It's important to note that patients in cases 6, 7, and 8 underwent fistula procedures that had failed in the past. Given this, it is notable that Kshara Sutra therapy produced complete recovery, indicating its efficacy as a backup plan for care when other approaches are unsuccessful. This is consistent with a study that found that Kshara Sutra therapy had a success rate of 92.9 percent in patients who had previously had unsuccessful procedures[27].

Revolutionizing Fistula Treatment: A Case Series on the Application of Kshara Sutra Therapy

Patients in cases 4 and 10 both had complicated transphincteric horseshoe fistulas. Due to their complex structure, such fistulas are frequently difficult to treat and heal. However, it took three to five months for all patients to fully recover. This backs up findings from a research that showed Kshara Sutra therapy was effective for treating individuals with complicated fistulas.

When analysing case 9, it is important to note that the fistula changed over time with the use of Kshara Sutra therapy from a difficult transphincteric fistula to a simple intersphincteric fistula, allowing a simple laying open of the tract[24]. This shows how this therapy has the potential to make the anatomy of complicated fistulas simpler, making subsequent interventions less difficult. Further research is required to fully understand the mechanisms underlying this simplification[21].

Last but not least, one of the main benefits of Kshara Sutra therapy is how quickly the fistulas healed in each case. Traditional fistula treatment techniques frequently entail protracted recuperation periods and increase morbidity. These examples of the benefit of Kshara Sutra therapy show how it can improve patients' quality of life and hasten their return to regular activities[28], [29].

Overall, these findings highlight the Kshara Sutra therapy's potential advantages in treating a variety of fistula presentations, including difficult instances and those that have not responded to other therapies. These results should be combined, and the usefulness of the therapy in other clinical contexts should be investigated in larger, randomised studies[30].

CONCLUSION

Our case series confirms that the Kshara Sutra treatment has the therapeutic ability to manage a range of anal fistulas, from straightforward to complex presentations. Even in patients who had repeated unsuccessful procedures in the past or had complicating conditions like diabetes, we always saw complete closure of the fistulas. Additionally, the length of the treatment was quite brief, resulting in a speedy patient recovery and little interference with their normal routines.

Importantly, no severe adverse events were noticed at any point during the course of the treatment, demonstrating the safety and acceptability of this approach. Additionally, the therapy demonstrated promise in the ability to reduce the complexity of complex fistulas, enabling, if required, more basic surgical operations.

Even though these results are encouraging, it's important to keep in mind that there are just a few patients in this case series. Additional research including bigger patient groups and randomised controlled trials are required in order to establish findings about the efficacy and safety of Kshara Sutra treatment that are more generalizable.

In conclusion, our findings add to the expanding body of research that shows Kshara Sutra therapy is effective in treating anal fistulas. This traditional medical practise may in fact offer a powerful and secure substitute for common surgical procedures, potentially altering how this difficult condition is managed.

Limitations of the Study

Our case series shows promising outcomes for the application of the Kshara Sutra in the treatment of anal fistulas, however there are certain restrictions. First of all, the sample size was very modest, and every patient received care at the same facility. As a result, the findings might not apply to all patients with anal fistulas. Second, there was no control group to use as a benchmark. More rigorous proof of the Kshara Sutra therapy's effectiveness would come from additional randomised controlled trials contrasting it with traditional surgical techniques. Finally, even though every patient said they had fully recovered, longer-term monitoring would be necessary to check for any recurrence.

Future Directions

The results of this study suggest more investigation into Kshara Sutra therapy as a form of anal fistula therapy. To confirm the findings of this study, it would be intriguing to undertake multi-center randomised controlled trials. The precise processes by which the Kshara Sutra promotes wound healing should also be clarified in additional research as this knowledge may help to advance the method and lead to the creation of novel treatments. To evaluate the risk of recurrence after Kshara Sutra therapy, long-term follow-up research would also be helpful.

Acknowledgements

In order to better the lives of others, we would like to convey our gratitude to the patients who took part in this study and volunteered to share their personal experiences. We also thank our colleagues who have contributed knowledge and insight that have considerably aided the research as well as the clinical professionals that cared for these patients.

Declaration of Conflict of Interest

Regarding the research, writing, and publication of this paper, the authors declare that they have no potential conflicts of interest.

Revolutionizing Fistula Treatment: A Case Series on the Application of Kshara Sutra Therapy

REFERENCES

- 1) H. Abcarian, "Anorectal infection: abscess–fistula," *Clin. Colon Rectal Surg.*, vol. 24, no. 01, pp. 14–21, 2011.
- 2) A. L. K. E. Ali, M. P.-K. Wong, and I. Sagap, "The Value of Cutting Seton for High Transsphincteric Anal Fistula in the Era of Its Misery," *Malaysian J. Med. Sci. MJMS*, vol. 29, no. 1, p. 55, 2022.
- 3) A. Amato *et al.*, "Evaluation and management of perianal abscess and anal fistula: SICCR position statement," *Tech. Coloproctol.*, vol. 24, pp. 127–143, 2020.
- 4) A. Amato *et al.*, "Evaluation and management of perianal abscess and anal fistula: a consensus statement developed by the Italian Society of Colorectal Surgery (SICCR)," *Tech. Coloproctol.*, vol. 19, pp. 595–606, 2015.
- 5) M. Amir, A. K. Singh, and M. Shekhar, "SIMPLIFIED TREATMENT FOR DIVERSIFIED FISTULA IN ANO," 2021.
- 6) P. Bapat, V. Bapat, and D. S. Phalgune, "Pilonidal sinus extended to create transsphincteric anal fistula treated by Kshara Sutra (A medicated herbal seton) without antibiotics: A rare case report," *Indian J. Colo-Rectal Surg.*, vol. 4, no. 3, pp. 73–75, 2021.
- 7) S. Bhusari, K. Nikam, and P. Wakte, "Anal fistula: a comprehensive review," *Pharma Innov. J.*, vol. 8, no. 1, pp. 201–208, 2019.
- 8) A. M. Alwan, D. Rokaya, G. Kathayat, and J. T. Afshari, "Onco-immunity and therapeutic application of amygdalin: A review," *J. Oral Biol. Craniofacial Res.*, 2022.
- 9) A. H. Demirel and K. Seyfettin, "Silver nitrate cauterization for anal fistulas with high blind tract chemical therapy in complicated anal fistulas," *Euroasian J Hepato-Gastroenterol*, vol. 3, pp. 49–53, 2013.
- 10) K. Faridi, P. Sreenadh, V. Mahanta, and R. Sherkhane, "Management of transsphincteric fistula-in-ano by modified conventional Ksharasutra therapy: A case report," *J. Ayurveda Case Reports*, vol. 4, no. 3, p. 95, 2021.
- 11) D. C. Goan, "A COMPERATIVE STUDY OF LIGATION OF INTERSPHINCTERIC FISTULA TRACT (LIFT) WITH CONVENTIONAL TREATMENT OF KSHARASUTRA THERAPY IN THE MANAGEMENT OF FISTULA IN ANO: A CLINICAL STUDY," 2021.
- 12) D. C. Goan, "SPHINCTER TONE OF PATIENTS WITH FISTULA-IN-ANO TREATED BY KSHARASUTRA THERAPY WITH THE HELP OF HIGH RESOLUTION ANAL MANOMETRY: A CLINICAL STUDY," 2021.
- 13) T. M. Hammond and P. J. Lunniss, "Principles and contemporary management of anal fistulas," *Gastrointest. Nurs.*, vol. 5, no. 2, pp. 32–40, 2007.
- 14) K. S. Ho *et al.*, "Prospective randomised trial comparing ayurvedic cutting seton and fistulotomy for low fistula-in-ano," *Tech. Coloproctol.*, vol. 5, pp. 137–141, 2001.
- 15) M. IBRAHIM, M. YASSER, and A. SALEM, "Retrospective Evaluation of Outcome of Rerouting Technique in Management of Horseshoe Perianal Fistula, Single Institution Experience," *Med. J. Cairo Univ.*, vol. 89, no. June, pp. 505–511, 2021.
- 16) L. Kalal and A. Kembhavi, "A comparative clinical study on the effect of Vibhitaki Ksharasutra and Apamarga Ksharasutra in the management of Bhagandara (Fistula-In-Ano)," *J. Ayurveda Integr. Med. Sci.*, vol. 3, no. 06, pp. 11–16, 2018.
- 17) S. Lalhruaizela, "Endofistula laser ablation of fistula-in-ano: a new minimally invasive technique for the treatment of fistula-in-ano," *Ann. Coloproctol.*, vol. 38, no. 4, pp. 301–306, 2021.
- 18) J. Martellucci and M. L. Vuolo, "The Seton in Anal Fistula Management," *Anal Fistula Abscess*, pp. 1–14, 2020.
- 19) A. A. A. MB and M. H. Patel, "Management of high anal Fistula by Kshar Sutra," *Texas J. Med. Sci.*, vol. 13, pp. 124–131, 2022.
- 20) H. Nazari *et al.*, "Advancing Standard Techniques for Treatment of Perianal Fistula; When Tissue Engineering Meets Seton: When tissue engineering meets seton for perianal fistula," *Heal. Sci. Rev.*, p. 100026, 2022.
- 21) A. Ommer *et al.*, "German S3 guidelines: anal abscess and fistula (second revised version)," *Langenbeck's Arch. Surg.*, vol. 402, pp. 191–201, 2017.
- 22) H. K. Panigrahi, M. R. Rani, and M. M. Padhi, "Clinical Evaluation of Kshara sutra Therapy in the management of Bhagandara (Fistula-in-Ano)-A prospective study," *Anc. Sci. Life*, vol. 28, no. 3, p. 29, 2009.
- 23) A. A. J. Pushpakumara and D. J. Anthony, "Anal manometry study in guggulu based kshara sutra in the management of fistula in ano," *SLJIM*, p. 16.
- 24) B. RajaRam, A. Upendar, D. R. Kumar, M. Venkanna, and R. J. Prasad, "Combined Therapy Approach of Treatment for Complex Anal Fistula: A Prospective Study," *J. Chalmeda Anand Rao Inst. Med. Sci. Vol*, vol. 7, no. 1, 2014.
- 25) P. B. Ramesh, "Anal fistula with foot extension—Treated by kshara sutra (medicated seton) therapy: A rare case report," *Int. J. Surg. Case Rep.*, vol. 4, no. 7, pp. 573–576, 2013.
- 26) J. A. Rizzo, A. L. Naig, and E. K. Johnson, "Anorectal abscess and fistula-in-ano: evidence-based management," *Surg. Clin.*, vol. 90, no. 1, pp. 45–68, 2010.
- 27) A. de S. Rós, C. H. M. dos Santos, D. M. Dourado, M. S. da Silva-Neto, I. Caldeira, and L. de O. Furtado, "Can

Revolutionizing Fistula Treatment: A Case Series on the Application of Kshara Sutra Therapy

stryphnodendron adstringens extract improve the results of fistulotomy followed by primary sphincteroplasty in the treatment of transsphincteric fistulae?," *ABCD. Arq. Bras. Cir. Dig. (São Paulo)*, vol. 33, 2020.

- 28) P. K. M. Shankar, G. N. SreeDeepthi, K. S. Rohit, and G. K. Swamy, "Ayurvedic management of fistula in ano: A systematic review protocol," *J Res Ayurvedic Sci*, vol. 3, pp. 100–105, 2019.
- 29) G. Subhas, J. Singh Bhullar, A. Al-Omari, A. Unawane, V. K. Mittal, and R. Pearlman, "Setons in the treatment of anal fistula: review of variations in materials and techniques," *Dig. Surg.*, vol. 29, no. 4, pp. 292–300, 2012.
- 30) Q. Wang, Y. He, and J. Shen, "The best surgical strategy for anal fistula based on a network meta-analysis," *Oncotarget*, vol. 8, no. 58, p. 99075, 2017.



There is an Open Access article, distributed under the term of the Creative Commons Attribution – Non Commercial 4.0 International (CC BY-NC 4.0) (<https://creativecommons.org/licenses/by-nc/4.0/>), which permits remixing, adapting and building upon the work for non-commercial use, provided the original work is properly cited.